

Collateral thermal injury during endoscopic skull base surgery from endonasal CO₂ laser and coblation

D CHIN^{1,2}, K SNIDVONGS^{3,4}, R SACKS^{3,5,6}, R J HARVEY^{1,3,7}

¹Department of Otolaryngology, Head, Neck and Skull Base Surgery, St Vincent's Hospital, Sydney, Australia, ²Department of Otolaryngology, Head and Neck Surgery, Changi General Hospital, Singapore, ³Advanced School of Medicine, Macquarie University Hospital, Sydney, Australia, ⁴Faculty of Medicine, Chulalongkorn University, Bangkok, Thailand, ⁵Faculty of Medicine, The University of Sydney, ⁶Department of Otolaryngology, Head and Neck Surgery, Concord Repatriation General Hospital, Sydney, and ⁷Faculty of Medicine, University of New South Wales, Sydney, Australia

Abstract

Introduction: Effective tissue removal techniques are essential in endoscopic skull base surgery. Improvements in technology permit more accurate application of CO₂ laser and coblation during endonasal procedures. This study assessed the thermal injury patterns associated with fibre CO₂ laser and coblation.

Methods: Fresh frozen cadaveric heads were used. Mucosal removal was performed at the ethmoid roof. Structured lesions were created using either CO₂ laser or coblation. The corresponding thermal injury patterns on dural tissue were assessed and compared between the two groups.

Results: Five cadaveric heads were obtained; five sides received CO₂ laser lesions and five coblation lesions. Forty per cent ($n =$ two sides) of the CO₂ specimens had macroscopic foci of grey-black discolouration on the dural aspect. No macroscopic dural changes were seen in the coblation specimens.

Conclusion: Dural injury was seen following CO₂ laser use despite attempts to avoid it. Both CO₂ laser and coblation have their advantages; however, the lower thermal working power of coblation and superior depth control may make it more suitable for endoscopic endonasal periorbital and peridural surgery.

Key words: Endoscopic Surgical Procedures; Skull Base; Lasers; Injuries

Introduction

Coblation (also known as electrodissection) and flexible fibre CO₂ laser are novel technologies with potential uses in functional endoscopic sinus surgery (FESS) and endoscopic skull base surgery. Temperature-limited tissue ablation with minimisation of collateral thermal injury has been advocated as the key advantage of coblation.¹ Recent studies on healing of coblation wounds in rabbit and sheep sinus mucosa indicate appropriate mucosal healing after coblation injury.^{2,3} Importantly, longer duration of coblation application does not result in deeper injury. In tandem with studies on safety, the use of coblation in FESS and endoscopic skull base surgery has been increasing, with consistent reports of low intra-operative blood loss, and one report of shorter operative time in reducing encephalocoeles compared with bipolar cautery.^{4–7}

There are fewer studies on the use of CO₂ laser in the sinonasal cavity, as flexible fibre lasers and hand-pieces (which facilitate endonasal manoeuvrability,

improving ease of delivery) have been introduced only recently.^{8,9} However, precise cutting and coagulation have been reported, especially when creating a transsphenoidal window for sellar lesions.⁸

Patterns of thermal injury differ between the two devices. In animal studies of coblation, lesions applied to the lamina papyracea were not associated with any histological changes in the adjacent orbit.^{2,3} The ethmoid skull base is another site of extremely thin bone at risk of inadvertent intracranial thermal injury. There are currently no reports on associated dural changes following either coblation or CO₂ laser use at the ethmoid skull base.

The aim of this study was to describe the depth of injury resulting from coblation and CO₂ laser use at the ethmoid skull base in fresh cadaveric specimens.

Materials and methods

The study was performed on fresh frozen cadaveric heads. In each specimen side, wide sphenoidotomy,

removal of all ethmoid partitions and Draf 2a frontal sinusotomy was performed so as to obtain an unobstructed view of the entire medial orbital wall and ethmoid roof. Mucosal removal was performed over an area bounded by the anterior ethmoidal artery anteriorly, attachments of the middle and superior turbinates medially, junction of the lamina papyracea and the fovea ethmoidalis laterally, and the plane of the face of the sphenoid posteriorly.

In each cadaveric head, the mucosa removal described above was performed using laser on one side and coblation on the other. While method and side allocation was not randomised, pairing of the mucosa and skull base was performed to minimise the effect of intrinsic differences for each specimen side. The characteristics of the cadavers in each group are shown in Table I.

Each lesion was created using either CO₂ laser (AcuPulse WaveGuide CO₂ Laser; Lumenis, Santa Clara, California, USA) or coblation (Coblator PROcise XP Plasma Wand; Arthrocare, Austin, Texas, USA). Carbon dioxide laser was delivered using the AcuPulse WaveGuide laser fibre system (super pulse; repeat mode; 4.0 W; spot size, 320 µm; time on, 0.20 seconds; time off, 0.10 seconds). A power of 4.0 W was chosen as this was the lower end of the power range used at the pituitary sella in Jayarao and colleagues' report.⁸ For the Coblator, the standard settings (i.e. ablation, 7; coagulation, 3) were used (Figure 1). The CO₂ laser or Coblator was applied within the defined anatomical limits until no further mucosa was observed endoscopically.

For coblation specimens, the ethmoid roof mucosa changed colour to grey-white as coblation was applied with light, brushing strokes. At the end-point of application (i.e. no further change noted), complete mucosal removal was achieved (Figure 1a and 1c).

The CO₂ laser fibre delivery system was able to deliver point lesions with submillimetre precision, using the HeNe aiming beam. Each lesion resulted in gradual charring with shrinkage of the tissue, accompanied by a small plume. At the end-point of application, there was no observable change to the

remaining layer of char on the ethmoid roof (Figure 1b and 1d).

After the lesions were created, each ethmoid roof was resected by dissecting around the perimeter of the ethmoid skull base, using a combination of cutting endoscopic instruments and a 4 mm diamond burr where required. Dural cuts were made with endoscopic scissors.

High definition digital photographs of the sinus and dural aspects of each dissected specimen side were obtained. The photographs, under ×10 magnification, were presented in a randomised fashion to an assessor (the second author) who was blinded to the dissection technology used. The assessor was asked to determine whether macroscopically visible thermal injury was present or absent.

Histological assessment of the specimens was not performed, as the aim of this study was to ascertain macroscopic changes. Furthermore, any microscopic changes would have been difficult to interpret in a fresh cadaveric specimen.

Results

Ten cadaveric head specimen sides were obtained; five received CO₂ laser and five coblation. Both the Coblator PROcise XP and the AcuPulse WaveGuide were easily manoeuvred within the sinonasal cavity under endoscopic vision.

On macroscopic examination, no visible tissue remnants were observed on the inferior surface of any coblation specimen side. However, all five CO₂ laser specimens had a thin layer of char tissue on the inferior surface. The dural (superior) surface of all coblation specimen sides appeared normal (Figure 1e), while foci of black discolouration were observed on the dura in two of the five (40 per cent) CO₂ laser specimen sides (Figure 1f).

Discussion

Coblation and CO₂ fibre laser represent technological innovations with potential applications in FESS and endoscopic skull base surgery. Each offers unique advantages. Coblation technology enables controlled tissue removal within a 40–70°C range, with minimal circumferential and limited deep tissue injury.¹ Combined irrigation and suction enables the surgical bed to be kept clear. Additionally, the integrated bipolar diathermy facilitates haemostasis, reducing the need to change instruments. While the shaft of the Coblator PROcise XP wand is malleable, it is 3.9 mm in width and thus substantially larger than the laser delivery fibres. Additionally, the point of dissection is also 3.9 mm wide, compared with the 0.6 mm beam width of the CO₂ fibre laser.

Histological specimens from animal studies have demonstrated that coblation of inferior turbinate mucosa results in immediate loss of respiratory epithelium and thermal injury to underlying seromucinous glands; the depth of injury was dependent on

TABLE I
SPECIMEN AND LESION CHARACTERISTICS

Sp no	Sex	Age (y)	Side	Lesion type
1	M	73	R	CO ₂ laser
			L	Coblation
2	M	90	R	Coblation
			L	CO ₂ laser
3	F	63	R	CO ₂ laser
			L	Coblation
4	M	78	R	Coblation
			L	CO ₂ laser
5	F	92	R	CO ₂ laser
			L	Coblation

Sp no = specimen number; y = years; M = male; R = right; L = left; F = female

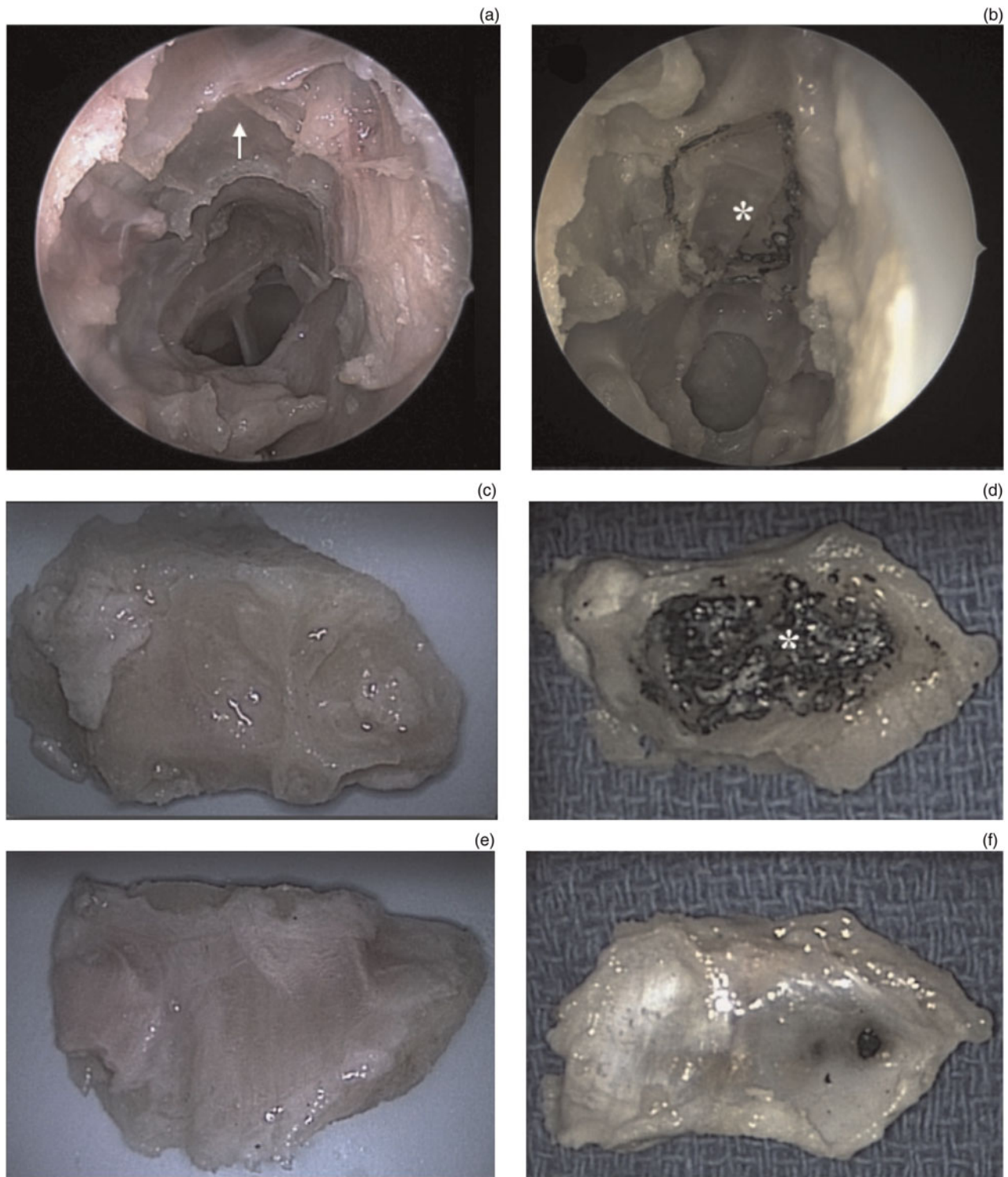


FIG. 1

Endoscopic views and pathological photographs presenting the application of coblation and flexible fibre CO₂ laser to the ethmoid skull base, showing: (a) mucosal ablation after coblation (arrow); (b) precise area of charring due to laser application (asterisk); (c) & (d) inferior surface of the ethmoid skull base after coblation and laser application, respectively; and (e) & (f) superior surface of the ethmoid skull base after coblation and laser application, respectively.

soft tissue type rather than duration of coblation application.³ Underlying bone demonstrated reactive, regenerative changes; however, a study of rabbit specimens observed only one case of histological changes beyond the maxillary sinus bony wall, even with prolonged application.² Therefore, it is

important that the characteristics at each potential site of application are well understood. In the present study of human cadaveric specimens, the macroscopic finding of complete removal of mucosa at the ethmoid roof, along with the lack of dural injury and low working temperature range,

suggest that coblation is ideally suited to, and safe for, bulky soft tissue removal at the skull base.

- **Coblation enables reduced thermal mucosal injury and less operative blood loss**
- **Endonasal fibre CO₂ laser enables precise, haemostatic dissection**
- **This study found macroscopic dural injury in 40 per cent of specimens after ethmoid skull base CO₂ laser**
- **No dural injury was seen after coblation**
- **Coblation may be more suitable for periorbital and peridural surgery**

The main advantages of the CO₂ laser have been listed as (1) haemostatic dissection of scar tissue, adhesions and tumour capsules, and (2) the ability to precisely dissect lesions from the surrounding soft tissue.⁹ Unlike its non-fibre predecessors, the flexible fibre system does not require 'line of sight' delivery, and the hand-piece allows the tip to be manipulated like a straight endoscopic instrument. Because CO₂ laser is absorbed to a large degree by water within cells, it has a shallow depth of penetration which confers relative safety, compared with other lasers. Submillimetre spot sizes enable lesions to be precisely positioned, minimising circumferential damage around the target. Multiple parameters can be adjusted to vary performance characteristics, in order to reduce collateral thermal injury at the target site. The superpulse mode used in the present study provides alternating laser time on and off and allows regular dissipation of thermal energy between applications. Studies on the use of flexible CO₂ laser in FESS are emerging and will provide more information on appropriate applications.

Conclusion

Both coblation and flexible fibre CO₂ laser have their advantages in FESS. However, in the present,

experimental study of thermal injury sustained during endoscopic skull base surgery using either CO₂ laser or coblation, dural injury was observed for CO₂ laser but not for coblation. The lower thermal working power of coblation may be more suitable for periorbital and peridural surgery.

References

- 1 Chinpairoj S, Feldman MD, Saunders JC, Thaler ER. A comparison of monopolar electrosurgery to a new multipolar electrosurgical system in a rat model. *Laryngoscope* 2001;**111**:213–17
- 2 Swibel Rosenthal LH, Benninger MS, Stone CH, Zacharek MA. Wound healing in the rabbit paranasal sinuses after Coblation: evaluation for use in endoscopic sinus surgery. *Am J Rhinol Allergy* 2009;**23**:360–3
- 3 Swibel-Rosenthal LH, Benninger MS, Stone CH, Zacharek MA. Wound healing in the paranasal sinuses after Coblation, Part II: evaluation for endoscopic sinus surgery using a sheep model. *Am J Rhinol Allergy* 2010;**24**:464–6
- 4 Kostrzewa JP, Sunde J, Riley KO, Woodworth BA. Radiofrequency coblation decreases blood loss during endoscopic sinonasal and skull base tumor removal. *ORL J Otorhinolaryngol Relat Spec* 2010;**72**:38–43
- 5 Ruiz JW, Saint-Victor S, Tessema B, Eloy JA, Anstead A. Coblation assisted endoscopic juvenile nasopharyngeal angiofibroma resection. *Int J Pediatr Otorhinolaryngol* 2012;**76**:439–42
- 6 Syed MI, Mennie J, Williams AT. Early experience of radio frequency coblation in the management of intranasal and sinus tumors. *Laryngoscope* 2012;**122**:436–9
- 7 Smith N, Riley KO, Woodworth BA. Endoscopic Coblator-assisted management of encephaloceles. *Laryngoscope* 2010;**120**:2535–9
- 8 Jayarao M, Devaiah AK, Chin LS. Utility and safety of the flexible-fiber CO₂ laser in endoscopic endonasal transsphenoidal surgery. *World Neurosurg* 2011;**76**:149–55
- 9 Agarwal G, Kupferman ME, Holsinger FC, Hanna EY. Sinonasal and nasopharyngeal applications of the hand-held CO₂ laser fiber. *Int Forum Allergy Rhinol* 2011;**1**:109–12

Address for correspondence:

Dr David Chin,
354 Victoria St,
Darlinghurst, NSW,
Australia 2010

Fax: +61 (0)293 609919

E-mail: drdavidchin@gmail.com

Dr D Chin takes responsibility for the integrity of the content of the paper

Competing interests: None declared

Enter a Title, ISSN, or search term to find journals or other periodicals:

0022-2151



[▶ Advanced Search](#)



Search My Library's Catalog: [ISSN Search](#) | [Title Search](#)

[Search Results](#)

Journal of Laryngology and Otology

Title Details

Table of Contents



Related Titles

- ▶ **Alternative Media Edition** (2)
- ▶ **Supplement** (1)

Lists

Marked Titles (0)

Search History

0022-2151 - (1)

Save to List Email Download Print Corrections Expand All Collapse All

▼ Basic Description

Title	Journal of Laryngology and Otology	
ISSN	0022-2151	
Publisher	Cambridge University Press	
Country	United Kingdom	
Status	Active	
Start Year	1887	
Frequency	Monthly	
Language of Text	Text in: English	
Refereed	Yes	
Abstracted / Indexed	Yes	
Serial Type	Journal	
Content Type	Academic / Scholarly	
Format	Print	
Website	http://journals.cambridge.org/action/displayJournal?jid=JLO	
Email	j.l.o@btconnect.com	
Description	Contains original scientific articles and clinical records in all fields of ontology, rhinology and laryngology.	

▶ Subject Classifications

▶ Additional Title Details

▶ Title History Details

▶ Publisher & Ordering Details

▶ Price Data

▶ Online Availability

▶ Abstracting & Indexing

▶ Other Availability

▶ Demographics

Save to List Email Download Print Corrections Expand All Collapse All