

CASE REPORT

Open Access



# Spinal myxopapillary ependymoma in an adult male presenting with recurrent acute low back pain: a case report

Dean Petersen<sup>1</sup> and Reidar P. Lystad<sup>2\*</sup> 

## Abstract

**Background:** Spinal intramedullary ependymomas are very rare and occur more commonly in the cervical and upper thoracic regions. These neoplasms tend to manifest in young adulthood, and patients typically present with mild clinical symptoms without objective evidence of neurologic deficits. The mean duration of symptoms is 40 months until the lesion is diagnosed.

**Case Presentation:** A 48-year-old male police officer was referred to a chiropractic clinic by a general practitioner for the evaluation of recurrent acute low back pain (LBP). Although the first episode of LBP was resolved, the clinical examination during the second episode revealed subtle changes that warranted referral to magnetic resonance imaging (MRI). The MRI revealed a spinal myxopapillary ependymoma.

**Conclusion:** Because the primary symptoms of spinal intramedullary ependymomas can mimic ordinary LBP presentations, in particular lumbar intervertebral disc herniations, clinicians need to be sensitive to subtle changes in the clinical presentation of LBP patients. Prompt referral to advanced medical imaging such as MRI and early neurosurgical intervention is key to achieve best possible outcomes for patients with spinal intramedullary ependymomas.

**Keywords:** Myxopapillary ependymoma, Spinal cord, Filum terminale, Neoplasm, Chiropractic

## Background

Primary intraspinal neoplasms are rare, with an age-adjusted incidence rate of 0.5 in females and 0.3 in males per 100,000 population per annum [1]. Ependymoma is the most common intramedullary spinal neoplasm in adults, accounting for up to 60 % of all glial spinal cord tumors [2]. Spinal ependymomas occur most commonly in the cervical and upper thoracic regions, and only 6.5 % involve either the distal thoracic cord or the conus medullaris [2, 3]. Myxopapillary ependymoma, a benign special variant of ependymoma that is thought to arise from ependymocytes of the filum terminale, constitutes approximately 13 % of all spinal ependymomas in this region [4].

Spinal myxopapillary ependymomas tend to manifest in adulthood (mean age, 35 years) and is more commonly seen in male patients [2]. Patients typically present with

mild clinical symptoms without objective evidence of neurologic deficits, which often results in a delay in diagnosis (mean duration of symptoms is 37 to 42 months) [2, 5]. At the time of diagnosis, patients typically have back or neck pain (67 %), sensory deficits (52 %), motor weakness (46 %), or bowel or bladder dysfunction (15 %) [2, 3]. Importantly, patients with a shorter duration of symptoms and less preoperative neurologic deficit tend to have better postoperative outcomes [2, 3].

Thus it becomes vital to promptly recognise important clues in the clinical presentation and evaluation that will lead to early diagnosis. Here we describe a rare case of an adult male with spinal myxopapillary ependymoma presenting as recurrent acute low back pain with subtle neurologic symptoms. The clinical presentation, chiropractic examination and management, imaging manifestations, and subsequent neurosurgical intervention and outcome are discussed below.

\* Correspondence: reidar.lystad@mq.edu.au

<sup>2</sup>Department of Chiropractic, Macquarie University, Sydney, Australia  
Full list of author information is available at the end of the article

## Case presentation

### Clinical history

A 48-year-old male police officer was referred to a chiropractic clinic by a general practitioner for the evaluation of acute low back pain (LBP) of two weeks duration. The patient reported that the LBP had come on after spending a 12-h night shift driving a patrol car. The LBP was described as diffuse and the patient reported sharp pain radiating down the left lateral thigh to the knee. The average pain intensity was rated as 6/10 on a visual analogue scale (VAS), but had progressed to 8/10 VAS at the time of presentation. The symptoms were aggravated by sitting, sleeping on the left side, and inactivity; while standing provided the most relief. The pain was worse in the morning, and improved only marginally during the day. Self-care with heat packs and over-the-counter non-steroidal anti-inflammatory drugs (6 × 200 mg ibuprofen tablets per day) provided only a 2-point reduction on the VAS. The patient denied the presence of any paraesthesia (e.g. pins or needles), saddle anaesthesia, loss or changes in bladder or bowel control, fever, or nocturnal pain. The patient reported an approximately 20 kg reduction in body weight over the past 10 months, which he attributed to dietary changes and uptake of a substantial exercise regimen.

The patient also complained of left-sided headaches in the suboccipital and temporal regions of three weeks duration. The headaches were accompanied by occasional dizziness (clarified to be a feeling of unease) that were aggravated by sustained awkward neck postures. He had a family history of hypertension, type 2 diabetes, and migraines. His grandmother had passed away from bowel cancer. The patient was currently being treated for haemochromatosis, for which he had been managed successfully for 8 years. The rest of the systems review was unremarkable.

### Physical examination

The physical examination revealed a marked antalgic posture to the right with limited active lumbar range of motion (ROM) in left lateral flexion and flexion (finger-to-floor reach was noted to be 2 cm above the knees). Coughing, sneezing, and Valsalva manoeuvre reproduced the LBP, but not the leg pain. Straight leg raise was positive for leg and back pain at 40° on the left and negative at 70° on the right. Bragard's test was positive on the left, while slump test and well leg raise were negative. Deep tendon reflexes were normal (2+) in both upper and lower limbs, except for the patella reflex on the left which was slightly diminished (1+). There was no decreased sensation to pin prick or vibration sense in either the upper or lower limbs; however, sensation to light touch was slightly decreased in the left L4 dermatome. Motor and cranial nerve exams were unremarkable. Blood pressure was 152/

92 mmHg and the resting heart rate was 75 bpm (measured in the sitting position).

The left temporal headache and dizziness (uneasiness) could be reproduced by combined flexion and 25° of rotation of the head to the right. The same manoeuvre on the contralateral side was pain free at 50° of rotation. There was marked tenderness to palpation over the left C2/3 zygapophysial joint and the lumbar spinous processes.

On the basis of the clinical presentation, history, and findings of the physical examination, a working diagnosis of posterolateral L3/4 intervertebral disc herniation affecting the left L4 nerve root was made, and a trial of conservative management was suggested to the patient. The patient also received a concurrent working diagnosis of cervicogenic headache. In addition, the patient was recommended to seek further evaluation of his blood pressure.

### Case management and outcome

Conservative management consisted of cryotherapy (ice packs), high-velocity, low-amplitude spinal manipulation to the lumbar region, isometric stretching, and neurodynamic mobilisation techniques (neural flossing). This passive care was complemented by ergonomic advice and a prescribed back extension exercise program. The patient received a total of 6 treatments over a 4-week period. After this treatment regimen the patient reported the LBP to be 1-2/10 VAS, with no pain radiating down the left leg, and that he was able to perform all activities of daily living. Neurodynamic tension tests (e.g. straight leg raise and Bragard's test) were negative. Lumbar spine ROM was improved (finger-to-floor reach 34 cm below the knees during flexion) and pain free.

The patient was discharged with a 4-week core muscle strengthening program and asked to return for a follow-up consultation after its completion, or earlier if symptoms returned. The patient returned asymptomatic after 4 weeks, and was able to satisfactorily perform the functional core strength tests.

### Second presentation

Two months after the last follow-up of the first episode of LBP, the patient presented to the chiropractic clinic with a new episode of acute LBP with pain radiating down the left leg. Similar to the first episode, the patient reported that the LBP had come on after an 8-h shift of driving a patrol car. However, this time the leg pain was radiating down the anterior aspect of the left thigh to the knee. He was taking prescription pain killers as directed by his general practitioner (1–2 tablets of 5 mg oxycodone [Endone, Aspen Pharmaceuticals] per 6 h). However, the medication provided minimal relief and the pain was unrelenting, worse at night, and interfering with his sleep. Bladder and bowel function was normal. The physical

examination mirrored the initial presentation but for two findings: (1) light touch was decreased in the left L3 and L4 dermatomes, and (2) slump test produced left anterior thigh pain radiating down to the left knee and lateral leg to the foot.

Because the patient now presented with indications of the possible involvement of multiple lumbar nerve roots, severe pain waking him up at night, and not responding to strong prescription pain medication, he was referred for magnetic resonance imaging (MRI) for an evaluation of possible compression of neurological structures at the L2 to L4 vertebral levels.

### Imaging

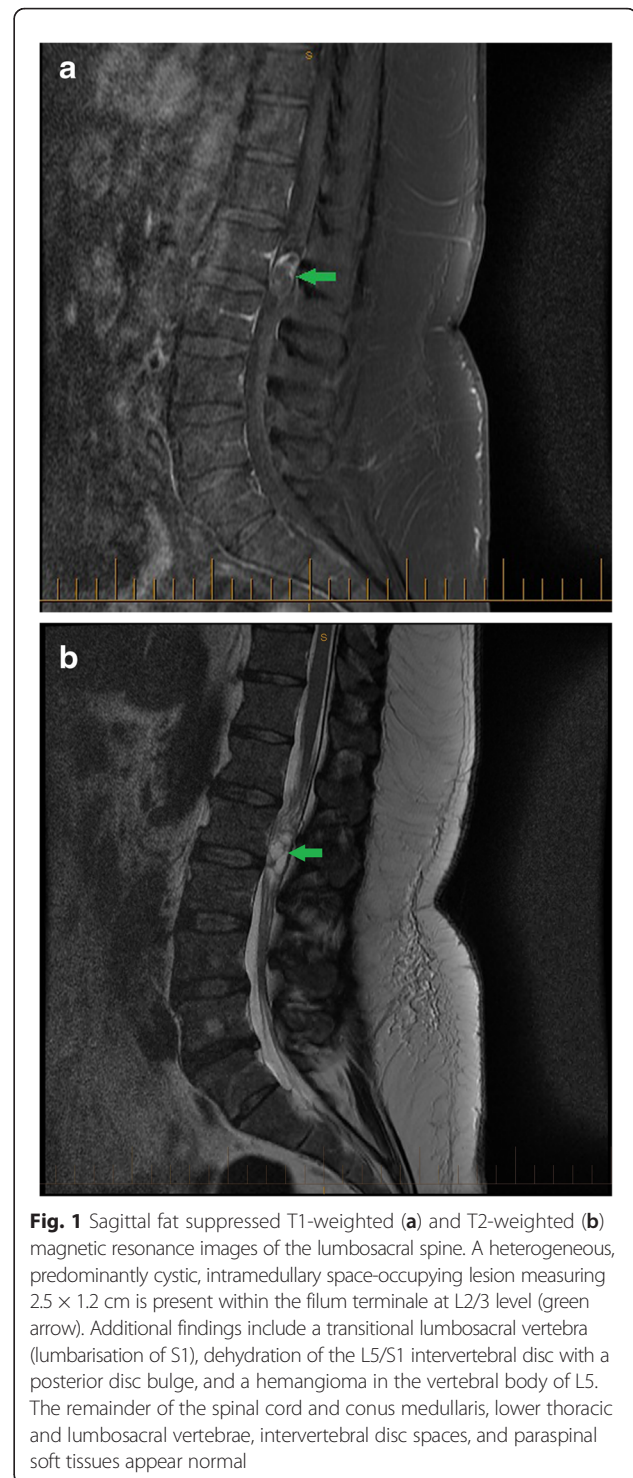
The MRI revealed a substantial heterogeneous space-occupying lesion with an intramedullary orientation within the filum terminale at the L2/3 vertebral level (see Fig. 1). The lesion measured approximately 2.5 cm × 1.2 cm in the craniocaudal and anterior-posterior dimensions, respectively. It appeared predominantly cystic on T2-weighted sequences and contained several fine internal septations. On post-contrast imaging, there was a heterogeneous enhancement of the lesion (predominantly peripheral), with a non-enhancing central aspect indicating a possible haemorrhagic or calcific component. The remainder of the spinal cord and conus medullaris appeared normal. Because the observed lesion most likely represented a myxoapapillary ependymoma, the patient was promptly referred for a neurosurgical consultation.

### Surgical intervention and outcome

The patient was scheduled for surgery the day after the neurosurgical consultation. A gross total resection was achieved and radiological adjunctive therapy was not pursued. Although the patient reported resolution of the neurological symptoms immediately after the surgery, low-grade LBP (3/10 VAS), described as a dull ache, still persisted for several weeks post-surgery. The patient received standard, post-surgical rehabilitation with a hospital-based physiotherapist for 6 months post-surgery. In long-term follow-ups at 6 and 12 months post-surgery, the patient reported no pain (0/10 VAS), with only a vague sensation of persistent numbness in the left anterior leg.

### Discussion

The present case highlights a number of important points: (1) the primary symptoms of intramedullary ependymomas of the caudal spinal cord can mimic ordinary LBP presentations, in particular lumbar intervertebral disc herniations; (2) clinicians need to be sensitive to subtle changes in the clinical presentation of LBP patients; and (3) prompt referral to advanced medical imaging such as MRI and early surgical intervention is key to achieve best



possible outcomes for patients like the one described in the present case.

LBP is a very common health problem, and one of the leading causes of activity limitation and work absence worldwide [6, 7]. It is not surprising, therefore, that LBP

is the most common complaint presenting to chiropractic clinics [8]. Although specific structural pathologies (e.g., intervertebral disk herniation or spinal stenosis) can be identified in a subset of patients presenting with LBP, the majority of cases (approximately 85 %) are referred to as nonspecific LBP [6, 9]. In the present case, the patient presented with typical LBP symptomatology with clinical findings indicative of a possible posterolateral L3/4 intervertebral disk herniation affecting the left L4 nerve root. Current evidence-based clinical practice guidelines recommend against the routine use of imaging in patients presenting with LBP [10, 11]. The patient was therefore offered conservative treatment consisting of a combination of passive and active care, to which he responded very well and was subsequently discharged.

At first glance the second episode appeared to be a typical recurrence of the first episode of LBP, with both the precipitating event and the clinical presentation of the second episode being very similar to the former. Furthermore, successful conservative management of the first episode could potentially lead to confirmation bias, that is, clinicians are likely to believe their working diagnoses are correct when their patients respond satisfactorily to care [12]. In the present case, however, a careful physical examination revealed subtle changes indicating the possible involvement of multiple lumbar spinal nerve roots. Moreover, the patient was not responding to strong prescription pain medication and the LBP would occasionally wake him up at night. Taken together, these were compelling reasons to suspect the presence of space-occupying pathologies such as spinal cord tumours and the patient was therefore referred to medical imaging.

It is difficult to estimate how often patients with an undiagnosed spinal ependymoma present to chiropractors with LBP because only a couple of cases have been reported in the literature to date. Lensgraf and Young described two cases: (1) a 46-year-old woman with 3–4 year history of intermittent LBP who eventually did not respond to conservative care; and (2) a 38-year-old man who presented with an unusual episode of LBP with leg pain [13]. In both cases the patient underwent surgical resection and was reported to be doing well at 12 months post-surgery [13]. Only the female patient received adjuvant radiation therapy [13].

In most jurisdictions, chiropractors can request advanced diagnostic imaging such as MRI. However, full government rebates for such referrals are only available in a few jurisdictions (e.g. Norway and Denmark). In Australia (the location of the present case), patients referred to MRI by chiropractors are not eligible for a Medicare rebate. Although the patient in the present case was both willing and able to pay for the MRI, this may of course not be true for all, or even the majority of, patients. It is, therefore, conceivable that such restrictions on advanced medical

imaging referrals can contribute to delayed diagnosis of some patients.

Early detection and treatment is key to achieve best possible patient outcomes for people with spinal intramedullary ependymoma. These neoplasms are best treated surgically and a complete resection indicates complete resolution for the vast majority of patients [14, 15]. Adjuvant radiation therapy is usually reserved for cases where only subtotal resection is possible, while chemotherapy is used more sparingly, for instance in young children who are more prone to negative side effects from radiation therapy [16]. Surgery should be performed early because patients with a shorter duration of symptoms and less preoperative neurologic deficit tend to have better postoperative outcomes [2, 3, 13, 15]. Although the mean duration of symptoms in patients with spinal ependymoma is more than 3 years [2, 5], the patient in the present case was diagnosed and referred for neurosurgical consultation within 6 months of onset of initial symptoms.

## Conclusions

The primary symptoms of spinal intramedullary ependymomas can mimic ordinary LBP, in particular lumbar intervertebral disc herniations. Clinicians need to be sensitive to subtle changes in the clinical presentation of LBP patients. Prompt referral to advanced medical imaging such as MRI and early surgical intervention is key to achieve best possible outcomes for patients with spinal intramedullary ependymomas.

## Ethics and consent

This study was approved by the Human Research Ethics Committee at Central Queensland University (ethics approval reference number: H15/08–194). Written informed consent was obtained from the patient for publication of this case report and any accompanying images. A copy of the written consent is available for review by the Editor-in-Chief of this journal.

## Competing interests

The authors declare that they have no competing interests.

## Authors' contributions

DP contributed to drafting the case presentation and discussion sections, and general editing of the manuscript. RPL contributed to the literature review, drafting the background and discussion sections, and general editing of the manuscript. All authors read and approved the final manuscript.

## Author details

<sup>1</sup>Private practice, Mackay, QLD, Australia. <sup>2</sup>Department of Chiropractic, Macquarie University, Sydney, Australia.

Received: 22 November 2015 Accepted: 2 March 2016

Published online: 18 April 2016

## References

1. Helseth A, Mørk SJ. Primary intraspinal neoplasms in Norway, 1955–1986, a population-based survey of 467 patients. *J Neurosurg.* 1989;71:842–5.



2. Ferrante L, Mastrorardi L, Celli P, Lunardi P, Acqui M, Fortuna A. Intramedullary spinal cord ependymomas: a study of 45 cases with long-term follow-up. *Acta Neurochir.* 1992;119:74–9.
3. Hoshimaru M, Koyama T, Hashimoto N, Kikuchi H. Results of microsurgical treatment for intramedullary spinal cord ependymomas: analysis of 36 cases. *Neurosurgery.* 1999;44:264–9.
4. Koeller KK, Rosenblum RS, Morrison AL. Neoplasms of the spinal cord and filum terminale: radiologic-pathologic correlation. *Radiographics.* 2000;20:1721–49.
5. Kucia EJ, Bambakidis NC, Chang SW, Spetzler RF. Surgical technique and outcomes in the treatment of spinal cord ependymomas, part 1: intramedullary ependymomas. *Neurosurgery.* 2011;68:57–63.
6. Hoy D, Brooks P, Blyth F, Buchbinder R. The Epidemiology of low back pain. *Best Pract Res Clin Rheumatol.* 2010;24:769–81.
7. Manchikanti L, Singh V, Falco FJ, Benyamin RM, Hirsch JA. Epidemiology of low back pain in adults. *Neuromodulation.* 2014;17 Suppl 2:3–10.
8. Lishchyna N, Mior S. Demographic and clinical characteristics of new patients presenting to a community teaching clinic. *J Chiropr Educ.* 2012;26:161–8.
9. da C Menezes Costa L, Maher CG, Hancock MJ, McAuley JH, Herbert RD, Costa LO. The prognosis of acute and persistent low-back pain: a meta-analysis. *CMAJ.* 2012;184:E613–24.
10. Koes BW, van Tulder M, Lin CW, Macedo LG, McAuley J, Maher C. An updated overview of clinical guidelines for the management of non-specific low back pain in primary care. *Eur Spine J.* 2010;19(12):2075–94.
11. Dagenais S, Tricco AC, Haldeman S. Synthesis of recommendations for the assessment and management of low back pain from recent clinical practice guidelines. *Spine J.* 2010;10(6):514–29.
12. Croskerry P. The importance of cognitive errors in diagnosis and strategies to minimize them. *Acad Med.* 2003;78(8):775–80.
13. Lensgraf AG, Young KJ. Ependymoma of the spinal cord presenting in a chiropractic practice: 2 case studies. *J Manipulative Physiol Ther.* 2006;29:676–81.
14. Klekamp J. Spinal ependymomas. Part 1: Intramedullary ependymomas. *Neurosurg Focus.* 2015;39(2):E6.
15. Tobin MK, Geraghty JR, Engelhard HH, Linninger AA, Mehta AI. Intramedullary spinal cord tumors: a review of current and future treatment strategies. *Neurosurg Focus.* 2015;39(2):E14.
16. Straus D, Tan LA, Takagi I, O'Toole JE. Disseminated spinal myxopapillary ependymoma in an adult at initial presentation: a case report and review of the literature. *Br J Neurosurg.* 2014;28(5):691–3.

Submit your next manuscript to BioMed Central and we will help you at every step:

- We accept pre-submission inquiries
- Our selector tool helps you to find the most relevant journal
- We provide round the clock customer support
- Convenient online submission
- Thorough peer review
- Inclusion in PubMed and all major indexing services
- Maximum visibility for your research

Submit your manuscript at  
[www.biomedcentral.com/submit](http://www.biomedcentral.com/submit)




[Log in to My Ulrich's](#)

Macquarie University Library --Select Language--

[Search](#) [Workspace](#) [Ulrich's Update](#) [Admin](#)

Enter a Title, ISSN, or search term to find journals or other periodicals:

2045-709X 

[▶ Advanced Search](#)



Search My Library's Catalog: [ISSN Search](#) | [Title Search](#)

[Search Results](#)

## Chiropractic & Manual Therapies

### Title Details

#### Lists

[Marked Titles \(0\)](#)

#### Search History

[2045-709X](#)  
[0165-070X](#)  
[1521-0227](#)  
[Frontiers in pharmacology](#)

Save to List Email Download Print Corrections Expand All Collapse All

#### ▼ Basic Description

<b>Title</b>	Chiropractic & Manual Therapies
<b>ISSN</b>	2045-709X
<b>Publisher</b>	BioMed Central Ltd.
<b>Country</b>	United Kingdom
<b>Status</b>	Active
<b>Start Year</b>	2011
<b>Frequency</b>	Irregular
<b>Language of Text</b>	Text in: English
<b>Open Access</b>	Yes <a href="http://chiromt.com">http://chiromt.com</a>
<b>Serial Type</b>	Journal
<b>Content Type</b>	Academic / Scholarly
<b>Format</b>	Online
<b>Website</b>	<a href="http://chiromt.com">http://chiromt.com</a>

#### ▶ Subject Classifications

#### ▶ Additional Title Details

#### ▶ Publisher & Ordering Details

#### ▶ Online Availability

Save to List Email Download Print Corrections Expand All Collapse All



## CHIROPRACTIC & MANUAL THERAPIES

### About **Chiropractic & Manual Therapies**

[Aims and scope](#) | [Open access](#) | [Article-processing charges](#) | [Indexing services](#) | [Publication and peer review process](#) | [Editorial policies](#) | [Citing articles in \*Chiropractic & Manual Therapies\*](#) | [Why publish your article in \*Chiropractic & Manual Therapies\*](#)

This page includes information about the aims and scope of *Chiropractic & Manual Therapies*, editorial policies, open access and article-processing charges, the peer review process and other information. For details of how to prepare and submit a manuscript through the [online submission system](#), please see the [instructions for authors](#).

#### Aims & scope

---

*Chiropractic & Manual Therapies* is ready to receive manuscripts on all aspects of evidence-based information that is clinically relevant to chiropractors, manual therapists and related health care professionals.

*Chiropractic & Manual Therapies* is an open access, peer-reviewed online journal that aims to provide chiropractors, manual therapists and related health professionals with clinically relevant, evidence-based information. Chiropractic and other manual therapies share a relatively broad diagnostic practice and treatment scope, emphasizing the structure and function of the body's musculoskeletal framework (especially the spine). The practices of chiropractic and manual therapies are closely associated with treatments including manipulation, which is a key intervention. The range of services provided can also include massage, mobilisation, physical therapies, dry needling, lifestyle and dietary counselling, plus a variety of other associated therapeutic and rehabilitation approaches.

*Chiropractic & Manual Therapies* is a continuation of the title *Chiropractic & Osteopathy (C&O)*. C&O was formerly known as *Australasian Chiropractic & Osteopathy (ACO)*, previously published by the Chiropractic & Osteopathic College of Australasia (COCA). Free text versions of ACO articles are available at <http://www.coca.com.au/index.php?ID=115>.

*Chiropractic & Manual Therapies* continues to serve as a critical resource in this field, and as an open access publication, is more readily available to practitioners, researchers and clinicians worldwide.

#### Open access

---

All articles published by *Chiropractic & Manual Therapies* are made freely and permanently accessible online immediately upon publication, without subscription charges or registration barriers. Further information about open access can be found [here](#).

Authors of articles published in *Chiropractic & Manual Therapies* are the copyright holders of their articles and have granted to a third party, in advance and in perpetuity, the right to use, reproduce or disseminate the article, according to the [BioMed Central copyright and license agreement](#).

#### Article-processing charges

---

The publication costs for *Chiropractic & Manual Therapies* are covered by Chiropractic & Osteopathic College of Australasia (COCA) and the European Academy of Chiropractic (EAC), so authors do not need to pay an article-processing charge.

#### Indexing services

---

Following publication in *Chiropractic & Manual Therapies*, the full-text of each article is deposited immediately and permanently archived in [PubMed Central](#), the US National Library of Medicine's full-text repository of life science literature, and also in repositories in e-Depot, the National Library of the Netherlands' digital archive of electronic publications. *Chiropractic & Manual Therapies* is included in PubMed and all major bibliographic databases. A complete list of indexing web services that include BioMed Central's journals can be found [here](#).

BioMed Central is working closely with [Thomson Reuters \(ISI\)](#) to ensure that citation analysis of articles published in *Chiropractic & Manual Therapies* will be available.

#### Publication and peer review process

---

## Criteria for publication

**Research:** reports of data from original research.

**Reviews:** comprehensive, authoritative, descriptions of any subject within the scope of the journal. These articles are usually written by opinion leaders that have been invited by the Editorial Board.

**Case reports:** reports of clinical cases that can be educational, describe a diagnostic or therapeutic dilemma, suggest an association, or present an important adverse reaction. It is important to note that case reports highlighting preventive or therapeutic intervention will, as a rule, not be published, because establishing the clinical merits of either requires stronger evidence.

**Commentaries:** short, focused and opinionated articles on any subject within the scope of the journal. These articles are usually related to a contemporary issue, such as recent research findings, and are often written by opinion leaders.

**Database articles:** describe a new database or a substantial improvement of an existing database.

**Debate articles:** present an argument that is not essentially based on practical research. Debate articles can report on all aspects of the subject including sociological and ethical aspects.

**Hypotheses:** short articles presenting an untested original hypothesis backed solely by previously published results rather than any new evidence.

**Methodology articles:** present a new experimental method, test or procedure. The method described may either be completely new, or may offer a better version of an existing method.

**Short reports:** brief reports of data from original research.

**Study protocols:** describe proposed or ongoing research, providing a detailed account of the hypothesis, rationale, and methodology of the study.

**Systematic reviews:** should be prepared in accordance with the [PRISMA](#) guidelines for systematic reviews. An additional file, linked from the Methods section, should reproduce all details concerning the search strategy. For an example of how a search strategy should be presented, see the [Cochrane Reviewers' Handbook](#).

The Editors of *Chiropractic & Manual Therapies* have produced some guidelines on [good scientific writing](#) to assist authors when preparing a manuscript for submission to the journal.

## Peer-review policies

Peer review in *Chiropractic & Manual Therapies* is designed to ensure that published articles are scientifically sound. The submitted manuscript will be sent to two external experts for evaluation of scientific significance and validity.

Peer reviewers will have three possible options for each manuscript: accept, accept with revision, and reject. Peer reviewers are asked to justify their decision.

Based on the critiques of the reviewers, the authors may choose to revise their manuscript and resubmit it for an additional review. *Chiropractic & Manual Therapies* allows authors a maximum of two revisions of a manuscript.

Authors will be able to check the progress of their manuscript through the submission system at any time by logging into [My Chiropractic & Manual Therapies](#), a personalized section of the site.

## Portability of peer review

In order to support efficient and thorough peer review, we aim to reduce the number of times a manuscript is re-reviewed after rejection from *Chiropractic & Manual Therapies*, thereby speeding up the publication process and reducing the burden on peer reviewers. Therefore, please note that, if a manuscript is not accepted for publication in *Chiropractic & Manual Therapies* and the authors choose to submit a revised version to another [BioMed Central journal](#), we will pass the reviews on to the other journal's editors at the authors' request. We will reveal the reviewers' names to the handling editor for editorial purposes unless reviewers [let us know](#) when they return their report that they do not wish us to share their report with another [BioMed Central journal](#).

## Reprints

High-quality, bound reprints can be purchased for all articles published. Please see our [reprints website](#) for further information about ordering reprints, and to enquire about further details, including fees, please contact BioMed Central's [reprint service](#).

## Supplements

*Chiropractic & Manual Therapies* will consider supplements based on proceedings (full articles or meeting abstracts), reviews or research. All articles submitted for publication in supplements are subject to peer review. Published supplements are fully searchable and freely accessible online and can also be produced in print. All full length articles (proceedings, reviews or research articles) are indexed by PubMed. PubMed displays the title of the supplement only in the case of meeting abstract collections. For further information, please [contact us](#).



## Editorial policies

---

Any manuscript, or substantial parts of it, submitted to the journal must not be under consideration by any other journal. In general, the manuscript should not have already been published in any journal or other citable form, although it may have been deposited on a preprint server. Information on duplicate/overlapping publications can be found [here](#). Authors are required to ensure that no material submitted as part of a manuscript infringes existing copyrights, or the rights of a third party.

Correspondence concerning articles published in *Chiropractic & Manual Therapies* is encouraged. A 'post a comment' feature is available on all articles published by *Chiropractic & Manual Therapies*. Comments will be moderated by the editorial office (see our [Comment policy](#) for further information) and linked to the full-text version of the article, if suitable.

## Editorial standards

BioMed Central is a member of the [Committee on Publication Ethics \(COPE\)](#) and endorses the World Association of Medical Editor (WAME) [Policy Statement on Geopolitical Intrusion on Editorial Decisions](#).

## Ethical guidelines

Submission of a manuscript to *Chiropractic & Manual Therapies* implies that all authors have read and agreed to its content, and that any experimental research that is reported in the manuscript has been performed with the approval of an appropriate ethics committee. Research carried out on humans must be in compliance with the [Helsinki Declaration](#), and any experimental research on animals must follow internationally recognized guidelines. A statement to this effect must appear in the Methods section of the manuscript, including the name of the body which gave approval, with a reference number where appropriate. Informed consent must also be documented. Manuscripts may be rejected if the editorial office considers that the research has not been carried out within an ethical framework, e.g. if the severity of the experimental procedure is not justified by the value of the knowledge gained.

For all articles that include information or clinical photographs relating to individual patients, written and signed consent from each patient to publish must also be made available if requested by the editorial staff.

*Chiropractic & Manual Therapies's* publisher, BioMed Central, has a legal responsibility to ensure that its journals do not publish material that infringes copyright, or that includes libellous or defamatory content. If, on review, your manuscript is perceived to contain potentially libellous content the journal Editors, with assistance from the publisher if required, will work with authors to ensure an appropriate outcome is reached.

The involvement of scientific (medical) writers or anyone else who assisted with the preparation of the manuscript content should be acknowledged, along with their source of funding, as described in the European Medical Writers Association (EMWA) [guideline](#) on the role of medical writers in developing peer-reviewed publications. If medical writers are not listed among the authors, their role should be acknowledged explicitly.

## Standards of reporting

*Chiropractic & Manual Therapies* supports initiatives aimed at improving the reporting of biomedical research. We recommend authors refer to the [EQUATOR](#) network website for further information on the available reporting guidelines for health research, and the [MIBBI](#) Portal for prescriptive checklists for reporting biological and biomedical research where applicable. Authors are requested to make use of these when drafting their manuscript and peer reviewers will also be asked to refer to these checklists when evaluating these studies. Checklists are available for a number of study designs, including randomized controlled trials ([CONSORT](#)), systematic reviews ([PRISMA](#)), observational studies ([STROBE](#)), meta-analyses of observational studies ([MOOSE](#)), diagnostic accuracy studies ([STARD](#)) and qualitative studies ([RATS](#)). For authors of systematic reviews, an additional file, linked from the Methods section, should reproduce all details concerning the search strategy. For an example of how a search strategy should be presented, see the [Cochrane Reviewers' Handbook](#).

For mutation nomenclature please use the guidelines suggested by the [Human Genome Variation Society](#), and the recommended gene name by consulting the appropriate genetic nomenclature database, e.g., HUGO for human genes, and the International Committee on Standardized Genetic Nomenclature for Mice. We encourage the use of standardized terms for human phenotypes, such as those proposed by the Elements of Morphology working group (see: <http://research.nhgri.nih.gov/morphology/index.cgi>).

Authors from pharmaceutical companies, or other commercial organizations that sponsor clinical trials, should adhere to the [Good Publication Practice guidelines for pharmaceutical companies](#), which are designed to ensure that publications are produced in a responsible and ethical manner. The guidelines also apply to any companies or individuals that work on industry-sponsored publications, such as freelance writers, contract research organizations and communications companies.

*Chiropractic & Manual Therapies* also supports initiatives to improve the performance and reporting of trials, part of which include prospective registering and numbering of clinical trials. The International Committee of Medical Journal Editors ([ICMJE](#)) has implemented the World Health Organisation (WHO) definition of clinical trials which states that a clinical trial is any research study that prospectively assigns human participants or groups of humans to one or more health-related interventions to evaluate the effects on health outcomes. This definition includes phase I to Phase IV trials.

Authors of protocols or reports of such clinical trials, where the primary purpose of the research is to understand the causes, development and effects of disease or to improve preventative, diagnostic or therapeutic interventions, must register their trials prior to submission in a suitable publicly available registry. In addition to accepting registration in any of the five existing

registries (<http://www.icmje.org/faq.html>), the ICMJE will accept registration of clinical trials in any of the primary registers that participate in the [WHO International Clinical Trials Registry Platform](#).

The trial registration number should be included as the last line of the manuscript abstract.

## Data and materials release

Submission of a manuscript to *Chiropractic & Manual Therapies* implies that readily reproducible materials described in the manuscript, including all relevant raw data, will be freely available to any scientist wishing to use them for non-commercial purposes. Nucleic acid sequences, protein sequences, and atomic coordinates should be deposited in an appropriate database in time for the accession number to be included in the published article. In computational studies where the sequence information is unacceptable for inclusion in databases because of lack of experimental validation, the sequences must be published as an additional file with the article.

Any 'in press' articles cited within the references and necessary for the reviewers' assessment of the manuscript should be made available if requested by the editorial office.

## Nucleotide sequences

Nucleotide sequences can be deposited with the [DNA Data Bank of Japan](#) (DDBJ), [European Molecular Biology Laboratory](#) (EMBL/EBI) Nucleotide Sequence Database, or [GenBank](#) (National Center for Biotechnology Information).

## Protein sequences

Protein sequences can be deposited with [SwissProt](#) or the [Protein Information Resource](#) (PIR).

The accession numbers of any nucleic acid sequences, protein sequences or atomic coordinates cited in the manuscript should be provided, in square brackets with the corresponding database name; for example, [EMBL:AB026295, EMBL:AC137000, DDBJ:AE000812, GenBank:U49845, PDB:1BFM, Swiss-Prot:Q96KQ7, PIR:S66116].

The databases for which we can provide direct links are: EMBL Nucleotide Sequence Database ([EMBL](#)), DNA Data Bank of Japan ([DDBJ](#)), GenBank at the NCBI ([GenBank](#)), Protein Data Bank ([PDB](#)), Protein Information Resource ([PIR](#)) and the Swiss-Prot Proteome Database ([Swiss-Prot](#)).

## Mass spectrometry

Mass spectrometry data should be supplied in the mzML format recommended by the HUPO Protein Standards Initiative Mass Spectrometry Standards Working Group guidelines (<http://www.psidev.info/index.php?q=node/80>). We also recommend that the data is deposited in the ProteomeExchange (<http://proteomexchange.org/>) through the PRIDE website (<http://www.ebi.ac.uk/pride/>), and protein interaction data can be submitted to members of the IMEx consortium (<http://www.imexconsortium.org/submit-your-data>).

## Structures

Protein structures can be deposited with one of the members of the [Worldwide Protein Data Bank](#). Nucleic Acids structures can be deposited with the [Nucleic Acid Database](#) at Rutgers. Crystal structures of organic compounds can be deposited with the [Cambridge Crystallographic Data Centre](#).

## Chemical structures and assays

Structures of chemical substances can be deposited with [PubChem Substance](#). Bioactivity screens of chemical substances can be deposited with [PubChem BioAssay](#).

## Functional genomics data (such as microarray, RNA-seq or ChIP-seq data)

Where appropriate, authors should adhere to the standards proposed by the [Functional Genomics Data Society](#) and must deposit microarray data in MIAME-compliant format in one of the public repositories, such as [ArrayExpress](#) or [Gene Expression Omnibus](#) (GEO). Deposition of high-throughput functional genomics sequencing data (such as RNA-Seq or ChIP-Seq data) with ArrayExpress or GEO in compliance with MINSEQE is also required.

## Computational modeling

We encourage authors to prepare models of biochemical reaction networks using the [Systems Biology Markup Language](#) and to deposit the model with the [BioModels database](#), as well as submitting it as an additional file with the manuscript.

## Plasmids

We encourage authors to deposit copies of their plasmids as DNA or bacterial stocks with [Addgene](#), a non-profit repository, or [PlasmID](#), the Plasmid Information Database at Harvard.

## Appeals and complaints

Authors who wish to appeal a rejection or make a complaint should, in the first instance, contact the Editor-in-Chief who will

provide details of the journal's complaints procedure.

## Competing interests

*Chiropractic & Manual Therapies* requires authors to declare any competing financial or other interest in relation to their work. All competing interests that are declared will be listed at the end of published articles. Where an author gives no competing interest the listing will read 'The author(s) declare that they have no competing interests'.

## Plagiarism detection

*Chiropractic & Manual Therapies's* publisher, BioMed Central, is a member of the [CrossCheck](#) plagiarism detection initiative. In cases of suspected plagiarism CrossCheck is available to the editors of *Chiropractic & Manual Therapies* to detect instances of overlapping and similar text in submitted manuscripts. CrossCheck is a multi-publisher initiative allowing screening of published and submitted content for originality.

## Citing articles in *Chiropractic & Manual Therapies*

---

Articles in *Chiropractic & Manual Therapies* should be cited in the same way as articles in a traditional journal. Because articles are not printed, they do not have page numbers; instead, they are given a unique article number.

Article citations follow this format:

Authors: Title. *Chiropr Man Therap* [year], [volume number]:[article number].

e.g. Roberts LD, Hassall DG, Winegar DA, Haselden JN, Nicholls AW, Griffin JL: Increased hepatic oxidative metabolism distinguishes the action of Peroxisome Proliferator-Activated Receptor delta from Peroxisome Proliferator-Activated Receptor gamma in the Ob/Ob mouse. *Chiropr Man Therap* 2009, **1**: 115.

refers to article 115 from Volume 1 of the journal.

## Why publish your article in *Chiropractic & Manual Therapies*?

---

### High visibility

*Chiropractic & Manual Therapies's* open access policy allows maximum visibility of articles published in the journal as they are available to a wide, global audience. Articles that have been especially highly accessed are highlighted with a '[Highly accessed](#)' graphic, which appears on the journal's contents pages and search results.

### Speed of publication

*Chiropractic & Manual Therapies* offers a fast publication schedule whilst maintaining rigorous peer review; all articles must be submitted online, and peer review is managed fully electronically (articles are distributed in PDF form, which is automatically generated from the submitted files). Articles are published with their final citation immediately upon acceptance in a provisional PDF form. The article will subsequently be published in both fully browsable web form, and as a formatted PDF; the article will then be available through *Chiropractic & Manual Therapies*, BioMed Central and PubMed Central and will also be included in PubMed.

### Flexibility

Online publication in *Chiropractic & Manual Therapies* gives authors the opportunity to publish large datasets, large numbers of color illustrations and moving pictures, to display data in a form that can be read directly by other software packages so as to allow readers to manipulate the data for themselves, and to create all relevant links (for example, to PubMed, to sequence and other databases, and to other papers).

### Promotion and press coverage

Articles published in *Chiropractic & Manual Therapies* are included in [article alerts](#) and regular email updates. Some may be included in abstract books mailed to academics and are highlighted on *Chiropractic & Manual Therapies's* pages and on the BioMed Central homepage.

In addition, articles published in *Chiropractic & Manual Therapies* may be promoted by press releases to the general or scientific press. These activities increase the exposure and number of accesses for articles published in *Chiropractic & Manual Therapies*. A list of articles recently press-released by journals published by BioMed Central is available [here](#).

### Copyright

Authors of articles published in *Chiropractic & Manual Therapies* retain the copyright of their articles and are free to reproduce or disseminate their work (for further details, see the [BioMed Central copyright and license agreement](#)).

For further information about the advantages of publishing in a journal from BioMed Central, please click [here](#).