




ORIGINAL ARTICLE

The effect of allergen immunotherapy in patients with central compartment atopic disease post-surgery

Christian M. Meerwein MD^{1,2}  | Peta-Lee Sacks MD¹  | Jacqueline Ho MD, PhD¹ |
 Christine Choy¹ | Larry Kalish MD^{1,3,4} | Raewyn G Campbell MD^{1,5} |
 Ray R. Sacks MD^{1,3,6} | Richard J Harvey MD, PhD^{1,4,6,7} 

¹Rhinology and Skull Base Research Group, St Vincent's Centre for Applied Medical Research, University of New South Wales, Sydney, Australia

²Department of Otorhinolaryngology, University Hospital Zurich and University of Zurich, Zurich, Switzerland

³Department of Otolaryngology, Head and Neck Surgery, Concord General Hospital, University of Sydney, Sydney, Australia

⁴Faculty of Medicine, University of Sydney, Sydney, Australia

⁵Department of Otolaryngology, Head and Neck Surgery, Royal Prince Alfred Hospital, Sydney, Australia

⁶Faculty of Medicine and Health Sciences, Macquarie University, Sydney, Australia

⁷School of Clinical Medicine, St Vincent's Healthcare Clinical Campus, Faculty of Medicine and Health, University of New South Wales, Sydney, Australia

Correspondence

Christian M. Meerwein, Rhinology and Skull Base Research Group, St Vincent's Centre for Applied Medical Research, University of New South Wales, 67 Burton Street Darlinghurst, Sydney, NSW 2010, Australia.

Email: chmeerwein@gmail.com

Abstract

Objective: To assess the effect of allergen immunotherapy (AIT) on patients with central compartment atopic disease (CCAD) and house dust mite (HDM) sensitization post-surgery.

Methods: A retrospective cohort of surgically treated, HDM-sensitized CRSwNP patients phenotyped as CCAD was assessed. Patients were divided into two groups based on whether they had AIT commenced as part of their surgical care. All AIT patients started immunotherapy prior to their surgery. The primary endpoint was reformation of middle turbinate (MT) edema 12 months postsurgery. Secondary endpoints were corticosteroid irrigation use (<4 times/week vs. ≥4 times/week, %) and the rhinologic domain of the 22-item sino-nasal outcome test (SNOT-22). Demographic characteristics, concomitant asthma, smoking status, history of aspirin-exacerbated respiratory disease, conjunctival symptoms, polysensitization, serum eosinophils (cell × 10⁹/L), tissue eosinophilia (% > 100/HPF), and serum IgE (kU/L) were also recorded.

Results: Eighty-six CCAD patients were assessed (41 ± 14 yrs, 64% female). AIT was applied in 37% (n = 32). Baseline features were similar apart from greater conjunctival symptoms (72 vs. 45%, p = 0.02) in the AIT group. At 12 months post-surgery, the AIT group has less MT edema (% ≥ diffuse 15.6 vs. 52.9, p < 0.01). Patients on AIT also had less pharmacotherapy requirements at 12 months (% ≥ 4/week, 37.5 vs. 79.6%, p < 0.01). The rhinologic symptoms were similar (21.1 ± 17.1 vs. 20.1 ± 21.6, p = 0.83).

Conclusions: Surgery and pharmacotherapy are effective in managing CCAD, but the addition of AIT improved allergic phenomenon and allowed de-escalation of topical therapy. Longer term studies are required to demonstrate further immunomodulation.

This is an open access article under the terms of the [Creative Commons Attribution-NonCommercial License](https://creativecommons.org/licenses/by-nc/4.0/), which permits use, distribution and reproduction in any medium, provided the original work is properly cited and is not used for commercial purposes.

© 2024 The Author(s). *International Forum of Allergy & Rhinology* published by Wiley Periodicals LLC on behalf of American Academy of Otolaryngic Allergy and American Rhinologic Society.

KEYWORDS

desensitization, hypersensitivity, immunologic, nasal surgical procedures, sinusitis

1 | INTRODUCTION

Central compartment atopic disease (CCAD) has emerged as a variant of primary diffuse type-2 dominant CRS and is a subtype of chronic rhinosinusitis (CRS) that is associated with polypoid tissue remodeling.^{1–4} It is characterized by localized inflammation and mucosal changes in the central compartment, which are thought to be triggered by exposure to inhalant allergens.^{4–6} Interestingly, even CCAD patients with classic endoscopic features but negative allergy sensitization on skin and serum show evidence of allergen-specific IgE's in their mucosal tissue.⁷

Disease defining endoscopic findings include edematous remodeling of the middle turbinate (MT), uncinate process, superior turbinate, and superior nasal septum.^{3,6,8,9} These alterations in the central compartment exist in both CCAD and to a lesser extent in patients with simple allergic rhinitis (AR).¹⁰ Therefore, CCAD and AR should be understood as a spectrum of tissue remodeling that occurs in inhalant allergy. Both conditions display similar allergen sensitivities.⁵

The optimal management of CCAD patients involves a disease-modifying strategy by treating the underlying inhalant allergy, which can successfully be achieved for the majority of all patients through allergy assessment and allergen-specific immunotherapy (AIT).^{11–13} Tissue remodeling changes secondary to prolonged allergen exposure can also result in both nasal obstruction and mechanical obstruction of sinuses. Thus, barotrauma is a common symptom reported by CCAD patients.⁹ At some point, many patients require endoscopic sinus surgery (ESS) and modification of turbinate hypertrophy to manage these symptoms. With regard to the surgical outcome it has been reported that CCAD patients generally experience longer-lasting benefits from ESS compared with other CRSwNP entities.¹⁴ However, the surgery does not modify the underlying allergic drive. The long-term success rate is anecdotally determined by the activity of the inhalant allergy, which drives central inflammation. So far, studies evaluating outcomes of surgically treated CCAD patients report concomitant AIT rates ranging from 34 to 50%, however, outcomes have not been stratified by AIT use.^{1,2}

The aim of this study was to determine whether the use of AIT as a concurrent treatment, along with surgery, influ-

enced the post-surgery progression of the disease in CCAD patients with house dust mite (HDM) sensitization.

2 | MATERIALS AND METHODS

A retrospective cohort study on surgically treated, allergically sensitized HDM patients fulfilling the definition of CCAD was performed. The retrospective cohort was created by a change in management strategy over time, as CCAD has become more established as disease phenotype. The study received ethics approval from the St. Vincent's Hospital Research Ethics Committee (2019/PID13822, 2021/PID02338) and patients provided informed consent for research data collection.

2.1 | Patient population

Adult CCAD patients (≥ 18 years) seen at a tertiary referral clinic were included. CCAD was defined as a condition with (1) a history of allergic nasal and non-nasal symptoms, (2) positive HDM epicutaneous skin prick testing and/or serum-specific IgE antibodies, and (3) endoscopic and radiologic tissue remodeling findings that had to include the MT with or without superior turbinate and superior nasal septum.³

2.2 | Treatment characteristics

All patients underwent ESS with the goal of creating a simple neo-sinus cavity as part of their management. All patients had sculpting of the MT to remove tissue remodeling. Most patients had Draf2a performed via a Carolyn's window technique.¹⁵ Draf3 was only applied to patients in whom the anterior–posterior dimension of the frontal recess was < 1 cm and for those patients with more severe disease.¹⁶ Airway procedures including septoplasty, or medial flap inferior turbinoplasty were performed, if required. Patients with less than 12 months of follow-up, or with CRS secondary to other conditions were excluded. All patients used a once-daily corticosteroid irrigation (1 mg budesonide, 1 mg betamethasone, or 1 mg mometasone in 240 mL solution) via irrigation bottle. After the first 3 months, patients were allowed to reduce irrigation-use

based on their symptoms. Antistaphylococcal antibiotics were given for 10 days and prednisone was given at 25 mg daily for 14 days. Follow-up appointments were scheduled at 1 and 3 weeks, 3 months, 6 months, and 12 months after surgery.

2.3 | Baseline characteristics

Demographic characteristics were recorded including patient age (years), gender (%female), previous sinus surgery (%), concomitant asthma (%), smoking status (%), history of aspirin-exacerbated respiratory disease (AERD) (%), and conjunctival symptoms (%). Asthma status was indicated either through current use of bronchodilator or inhaled corticosteroid therapy and/or a >15% change in FEV1 postbronchodilator on spirometry.¹⁷ Aspirin sensitivity was defined as a well-described history of bronchospasm after aspirin or nonsteroid anti-inflammatory use, or a positive oral or nasal lysine aspirin challenge test with a > 15% reduction in FEV1 or a > 40% increase in total nasal airway resistance on rhinomanometry.¹⁷ Smokers were defined as patients who smoked at least weekly or more and were actively smoking or had ceased in the past 12 months.

2.4 | Blood and allergic disease work-up

Perioperatively, the following variables were assessed: total IgE, (UI/mL), serum eosinophil count ($\times 10^9$ cells/L), serum-specific IgE antibodies for the four aeroallergen mixes (dustmite, grass mix, mold, animal epithelium) via automated immunoassay (ImmunoCap). A serum-specific IgE level of greater than 0.35 kU/L for any of these aeroallergens was considered a positive result and the patient classified as atopic. Epicutaneous allergy assessment was performed by a skin prick test. Evaluation was done on a panel of 16 allergens that corresponded to the 4 allergen mixes (dust mite, mold, animal, and grass). Details of skin prick testing were described before.⁸ The rate of polysensitization (%) was recorded. Tissue samples were taken intraoperatively and assessed using a structured synoptic reporting format for tissue degree of inflammation (mild, moderate, or severe).¹⁸ Eosinophil count was categorized as <10, 10–100, or >100 cells/high-powered field (HPF).¹⁸

2.5 | Allergen immunotherapy for HDM

Patients were divided into two groups based on whether they had HDM AIT commenced as part of their surgical care (AIT vs. no-AIT group). Allergen immunotherapy

(AIT) was administered via a once daily intake of a SLIT-tablet (Acarizax®, Seqirus, USA; Actair®, Stallergenes, Switzerland).

2.6 | Primary endpoint

2.6.1 | Assessment of MT edema/tissue remodeling at 12 months

Reformation of MT edema and remodeling was determined by the assessment of video recordings of sinus endoscopies performed during the patient's assessment 12 months after surgery. MT changes were categorized as based on an ordinal scale, which has been described previously (1 = normal, 2 = focal edema, 3 = multifocal edema, 4 = diffuse edema, 5 = polypoid mucosa) (Figure 1).⁸

2.7 | Secondary endpoints

2.7.1 | Patient-reported outcome measures

Preoperative patient-reported outcome measures (PROMs) were quantified using the 22-item sino-nasal outcome test (SNOT-22) completed by the patient prior as well as 1 year after surgery. The SNOT-22 consists of 22 questions that require the patient to rate the severity of a sinonasal disease outcome based on a 5-point ordinal scale (0 = no problem; 1 = very mild problem; 2 = mild or slight problem; 3 = moderate problem; 4 = severe problem; 5 = problem as bad as it can be). The SNOT-22 total score was calculated by the addition of the individual scores for all 22 items and ranges from 0 to 110. The rhinologic domain is a subset of the SNOT-22 calculated by the addition of the scores of 5 items from the SNOT-22: (1) need to blow nose, (2) nasal obstruction, (3) loss of smell/taste, (4) thick nasal discharge, and (5) facial pain/pressure. The rhinologic domain score ranges from 0 to 25. Higher PROM scores correlate to worse patient symptoms.

2.8 | Medication use

The extent of reliance on postoperative topical corticosteroid was defined as the weekly frequency of nasal corticosteroid irrigation use at the 12 months assessment. This outcome was dichotomized as ≥ 4 or < 4 corticosteroid irrigations per week to distinguish frequent and less frequent corticosteroid irrigation users. In the first 3 months post-surgery patients were recommended a daily corticosteroid irrigation frequency but after 3–6 months, those with normal mucosa on examination could de-escalate

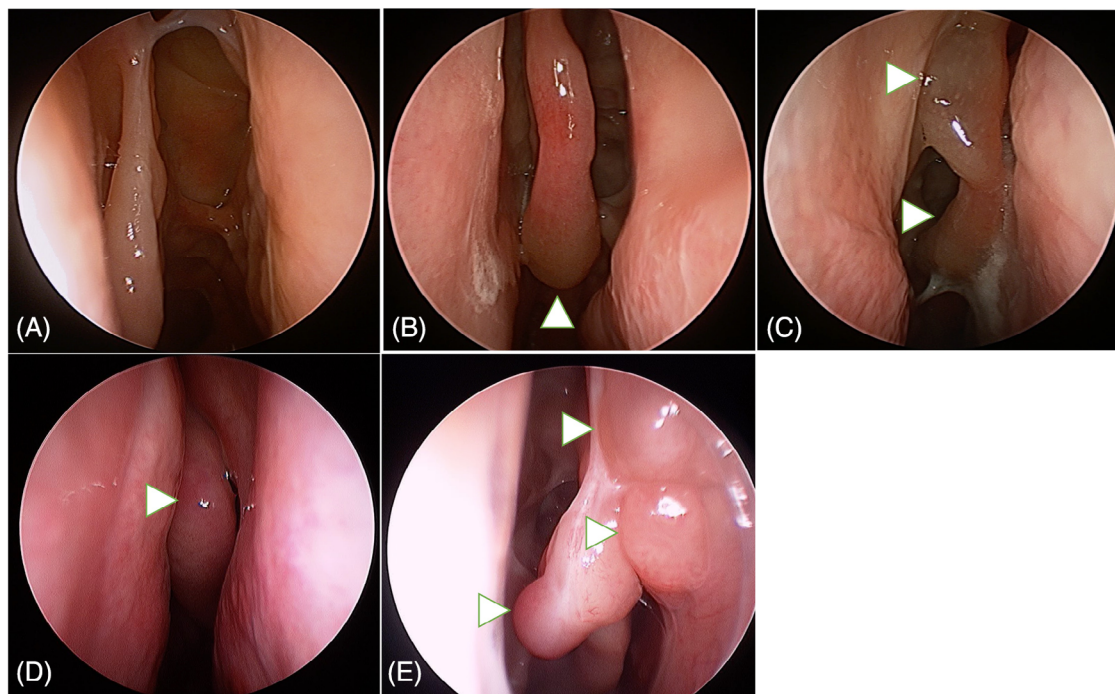


FIGURE 1 Examples of patients with normal configuration of the MT (A), focal edema (white arrowhead) (B), multifocal edema (white arrowheads) (C), diffuse edema (white arrowhead) (D) and polypoid edema with extension towards the nasal septum (white arrowheads) (E) at the 12 month assessment post-surgery. MT, middle turbinate.

their weekly usage of corticosteroid irrigation based on symptom control.¹⁹

2.9 | Statistical analysis

Parametric continuous variables were presented as mean \pm standard deviation, nonparametric measures as median and interquartile range and categorical results were presented as percentages (%) with 95% confidence interval. Means of variables with an abnormal distribution were analyzed using the independent *T*-test for two-group comparisons. The comparison of categorical variables was analyzed using the Fisher's exact or Chi-square test. Correlation of ordinal variables was calculated using Kendall's Tau-*b* test. Statistical significance was set at $p < 0.05$. Statistical analyses were performed using SPSS (version 29.0; IBM Corp, Armonk, NY).

3 | RESULTS

A total of 86 patients were assessed (mean age 41 ± 14 , 64% female). AIT was used in 37% ($n = 32$). Prior surgery had been performed in 43% of patients. Active asthma was seen in 55% of patients, with AERD present in 1%. Most patients, 90%, were nonsmokers. Conjunctival symp-

toms were present in 52% of all patients. Allergic workup revealed polysensitization in 57%.

3.1 | Comparison of population and disease baseline characteristics (AIT vs. no-AIT group)

Conjunctival symptoms were more common in the AIT group (72 vs. 45%, $p = 0.02$). There were no other differences in age, sex, rate of previous sinus surgery, asthma, smoking, AERD, rate of polysensitization, total IgE, serum eosinophil level, or tissue eosinophilia (Table 1).

3.2 | Comparison between groups (AIT vs. no-AIT group)

Reformation of MT edema was less common in patients with AIT compared with patients without AIT ($\% \geq$ diffuse 15.6 vs. 52.9, $p < 0.01$). Patients on AIT also had a lower use of ongoing pharmacotherapy at 12 months ($\% \geq 4/\text{week}$, 37.5 vs. 79.6%, $p < 0.01$). Rhinologic PROMs (rhinologic subdomain SNOT-22) were similar between AIT and no-AIT patients (21.1 ± 17.1 vs. 20.1 ± 21.6 , $p = 0.83$) (Table 2).

TABLE 1 Disease and baseline characteristics (n=86). AIT, allergen immunotherapy.

	Treatment group		p
	AIT	No-AIT	
n	32	54	
Age (yrs)	41 ± 14	44 ± 13	0.33
Sex (%F)	69	65	0.45
Previous sinus surgery (%)	56	57	0.92
Asthma (%)	41	48	0.33
Smoking (%)	14	10	0.46
AERD (%)	3	0	0.37
Conjunctival (any %)	72	45	0.02
Polysensitized (%)	44	63	0.06
Total IgE (IU/L)	313 ± 465	280 ± 360	0.72
Serum eosinophils (×10 ⁹ cells/L)	0.32 ± 0.2	0.47 ± 0.3	0.32
Tissue eosinophilia (%>100)	38	46	0.17

TABLE 2 Reformation of MT edema, PROMS and medication use at 12 months post-surgery.

	Treatment group		p
	AIT	No-AIT	
n	32	54	
MT edema			0.01
Normal	62.5	24.5	
Focal	6.3	11.3	
Multifocal	15.6	11.3	
Diffuse	15.6	47.2	
Polypoid	0	5.7	
Rhinologic domain (0–25)	7.1 ± 5.1	7.8 ± 6.8	0.67
SNOT-22 (0–110)	21.1 ± 17.1	20.1 ± 21.6	0.83
Corticosteroid irrigation use (%)			
<4 times/week	62.5	20.4	<0.01
≥4 times/week	37.5	79.6	

Abbreviations: AIT, allergen immunotherapy; MT, middle turbinate.

4 | DISCUSSION

This study demonstrates that the concurrent use of AIT in CCAD patients does improve allergy-driven tissue remodeling and allows de-escalation of treatment needs. A retrospective cohort was created by a change in clinical practice as the entity of CCAD became more defined in the authors practice and in the literature. Patients with CCAD were engaged in disease modifying interventions such as immunotherapy much earlier in management compared with historical treatment strategies.

Hallmark features of inhalant allergy include the presence of a pale, hypertrophied inferior turbinate head, cobblestoning of the mucosa and congestion, and edematous changes on the leading edge of the MT head.⁸

These changes can be explained by the deposition of inhaled aeroallergens, which triggers local allergic inflammation and leads to edema of the mucosa.²⁰ Previous studies found MT edema to be a strong diagnostic marker of inhalant allergy and introduced a 5-category scale with increasing severity of edema, ranging from focal to polypoid.^{6,8} The surgical strategy for the treatment of CCAD patients consists of the removal of any central compartment polypoid or edematous changes. This often involves trimming or sculpting the MT.^{1,14} Concomitantly, as these central compartment changes often lead to secondary obstruction and dysfunction of the sinuses, a neo-sinus cavity is established to resolve any form of pressure-induced symptoms, such as barotrauma.¹⁶ The surgical outcome of CCAD is more favorable compared with other phenotypical variants of CRSwNP. This has been shown for various objective outcome measures, such as polyp recurrence, need for revision surgery, need for oral steroid treatment and need for systemic antibiotic treatment.^{1,14} However, while surgery may remove the tissue remodeling it does little to change the inhalant allergy process that is thought to drive this condition. Without AIT, long-term treatment then only rests on ongoing topical therapy.

A recent study has investigated similarities between allergen sensitivity patterns of CCAD and AR and found a high degree of resemblance. Thereby, HDM and weed were by far the two most common allergens in the CCAD group, rendering the sensitization pattern of our study population representative for the underlying inhalant allergy.⁵ The assessment of our patients 12 months after surgically addressing central compartment edematous and polypoid changes revealed that the reformation of MT allergic changes in CCAD patients on AIT was significantly reduced, when compared with CCAD patients not on AIT. It has been well demonstrated that in HDM-sensitized AR patients, the use of AIT results in a significant decrease in nasal edema, secretions, and modified Lund-Kennedy score.²¹ Other landmark studies on the effect of SLIT in AR focused on symptom scores, rescue medication scores, onset of action, safety and patient-reported outcomes, rather than on endoscopic findings.^{22–24} As both patient groups in our study underwent the same surgical strategy and postoperative instructions with regard to topical therapy, the reduction of MT edema is most likely due to the effect of SLIT therapy.

Due to the retrospective design of our study, there are some inherent and noteworthy limitations. While the overall baseline characteristics between the two groups were very similar (Table 1), conjunctival symptoms were significantly more common in the AIT group compared with the no-AIT group. In contrast, the rate of polysensitization, as well as the absolute values for serum and tissue

eosinophilia, were increased in the no-AIT group compared with the AIT group, although not significantly. Whether this represents subtle differences between patient groups or the limitations of historically characterizing phenotypes is uncertain.

5 | CONCLUSION

Surgery and pharmacotherapy are effective in managing CCAD, but the addition of AIT improved allergic phenomenon and allowed de-escalation of topical therapy. Given the underlying pathophysiology of this disease, AIT as a disease modifying intervention should be considered in the management of CCAD. Longer term studies are required to demonstrate further immunomodulation.

CONFLICT OF INTEREST STATEMENT

Richard J. Harvey is consultant/advisory board with Medtronic, Novartis, Glaxo-Smith-Kline, and Meda Pharmaceuticals. He has been on the speakers' bureau for Glaxo-Smith-Kline, Astra-Zeneca, Meda Pharmaceuticals, and Seqirus. Larry Kalish is on the speakers' bureau for Viatrix, Stallergenens, and Seqirus Pharmaceuticals. Raewyn G. Campbell is on the speaker's bureau for Medtronic, Viatrix, and Glaxo-Smith-Kline. All other authors have no personal, financial, or institutional interest in any drugs, materials, or devices described in this article.

ORCID

Christian M. Meerwein MD  <https://orcid.org/0000-0002-8674-1007>

Peta-Lee Sacks MD  <https://orcid.org/0000-0001-7828-8305>

Richard J Harvey MD, PhD  <https://orcid.org/0000-0002-6942-8975>

REFERENCES

1. Steehler AJ, Vuncannon JR, Wise SK, DelGaudio JM. Central compartment atopic disease: outcomes compared with other subtypes of chronic rhinosinusitis with nasal polyps. *Int Forum Allergy Rhinol.* 2021;11(11). doi:10.1002/alr.22819
2. Sit A, Alvarado R, Earls P, et al. CCAD or eCRS: defining eosinophilic subpopulations in chronic rhinosinusitis. *Am J Rhinol Allergy.* 2023;37(4). doi:10.1177/19458924231155012
3. Grayson JW, Cavada M, Harvey RJ. Clinically relevant phenotypes in chronic rhinosinusitis. *J Otolaryngol Head Neck Surg.* 2019;48(1). doi:10.1186/s40463-019-0350-y
4. DelGaudio JM, Loftus PA, Hamizan AW, Harvey RJ, Wise SK. Central compartment atopic disease. *Am J Rhinol Allergy.* 2017;31(4). doi:10.2500/ajra.2017.31.4443
5. Tripathi SH, Ungerer HN, Rullan-Oliver B, et al. Similarities between allergen sensitivity patterns of central compartment atopic disease and allergic rhinitis. *Int Forum Allergy Rhinol.* 2022;12(10). doi:10.1002/alr.22983
6. Osie G, Wegrecki K, Alvarado R, et al. Features of inhalant allergy on nasal endoscopy: a systematic review and meta-analysis. *Rhinology.* 2022;60(5). doi:10.4193/Rhin22.066
7. Edwards TS, DelGaudio JM, Levy JM, Wise SK. A prospective analysis of systemic and local aeroallergen sensitivity in central compartment atopic disease. *Otolaryngol Head Neck Surg.* 2022;167(5). doi:10.1177/01945998221082554
8. Hamizan AW, Christensen JM, Ebenzer J, et al. Middle turbinate edema as a diagnostic marker of inhalant allergy. *Int Forum Allergy Rhinol.* 2017;7(1). doi:10.1002/alr.21835
9. Seresirikachorn Barinya, Alvarado Raquel, Perkovic Adam, et al. Central compartment atopic disease as a distinct clinical phenotype to classic type 2 or eosinophilic CRSwNP. *Submitted for publication, currently under review.* 2024.
10. White LJ, Rotella MR, Delgaudio JM. Polypoid changes of the middle turbinate as an indicator of atopic disease. *Int Forum Allergy Rhinol.* 2014;4(5). doi:10.1002/alr.21290
11. Greenhawt M, Oppenheimer J, Nelson M, et al. Sublingual immunotherapy: a focused allergen immunotherapy practice parameter update. *Ann Allergy Asthma Immunol.* 2017;118(3). doi:10.1016/j.anai.2016.12.009
12. Roberts G, Pfaar O, Akdis CA, et al. EAACI guidelines on allergen immunotherapy: allergic rhinoconjunctivitis. *Allergy.* 2018;73(4). doi:10.1111/all.13317
13. Orlandi RR, Kingdom TT, Smith TL, et al. International consensus statement on allergy and rhinology: rhinosinusitis 2021. *Int Forum Allergy Rhinol.* 2021;11(3). doi:10.1002/alr.22741
14. Guo Y, Nie Z, Chen C, et al. Outcomes of endoscopic sinus surgery in patients with central compartment atopic disease. *World Allergy Org J.* 2024;17(2). doi:10.1016/j.waojou.2023.100859
15. Seresirikachorn K, Sit A, Png LH, et al. Carolyn's window approach to unilateral frontal sinus surgery. *Laryngoscope.* 2023;133(10). doi:10.1002/lary.30569
16. Harvey RJ, Snidvongs K, Kalish LH, Oakley GM, Sacks R. Corticosteroid nasal irrigations are more effective than simple sprays in a randomized double-blinded placebo-controlled trial for chronic rhinosinusitis after sinus surgery. *Int Forum Allergy Rhinol.* 2018;8(4). doi:10.1002/alr.22093
17. Ho J, Li W, Grayson JW, et al. Systemic medication requirement in post-surgical patients with eosinophilic chronic rhinosinusitis*. *Rhinology.* 2021;59(1). doi:10.4193/Rhin20.073
18. Snidvongs K, Lam M, Sacks R, et al. Structured histopathology profiling of chronic rhinosinusitis in routine practice. *Int Forum Allergy Rhinol.* 2012;2(5). doi:10.1002/alr.21032
19. Grayson JW, Li W, Ho J, et al. Topography of polyp recurrence in eosinophilic chronic rhinosinusitis. *Int Forum Allergy Rhinol.* 2020;10(5). doi:10.1002/alr.22529
20. Inthavong K, Shang Y, Del Gaudio JM, et al. Inhalation and deposition of spherical and pollen particles after middle turbinate resection in a human nasal cavity. *Respir Physiol Neurobiol.* 2021;294. doi:10.1016/j.resp.2021.103769
21. Liu B, Feng J, Hu S. The role of nasal endoscopy in allergic rhinitis and house dust mite sublingual immunotherapy. *Int Arch Allergy Immunol.* 2021;182(8). doi:10.1159/000513810
22. Bergmann KC, Demoly P, Worm M, et al. Efficacy and safety of sublingual tablets of house dust mite allergen extracts in adults

- with allergic rhinitis. *J Allergy Clin Immunol*. 2014;133(6). doi:10.1016/j.jaci.2013.11.012
23. Sidenius K, Arvidsson P, Indbryn R, Emanuelsson CA. A real-life one-year non-interventional study assessing safety, tolerability, and treatment outcome of the SQ HDM SLIT-Tablet (Acarizax®) in house dust mite allergic rhinitis with or without asthma. *Pulm Ther*. 2021;7(1). doi:10.1007/s41030-021-00150-z
24. Okamoto Y, Kato M, Ishii K, Sato Y, Hata T, Asaka Y. Safety and effectiveness of a 300 IR house dust mite sublingual tablet: descriptive 4-year final analysis of a post-marketing surveil-

lance in Japan. *Immunotherapy*. 2023;15(16). doi:10.2217/imt-2023-0100

How to cite this article: Meerwein CM, Sacks P-L, Ho J, et al. The effect of allergen immunotherapy in patients with central compartment atopic disease post-surgery. *Int Forum Allergy Rhinol*. 2025;15:128–134. <https://doi.org/10.1002/alr.23459>