

Research Article

Cite this article: Atama N, Manu S, Ivande S, Roskopf S P, Matuschewski K, Schaer J (2019). Survey of *Hepaticystis* parasites of fruit bats in the Amurum forest reserve, Nigeria, identifies first host record for *Rousettus aegyptiacus*. *Parasitology* **146**, 1550–1554. <https://doi.org/10.1017/S0031182019000817>

Received: 11 March 2019
Revised: 7 May 2019
Accepted: 8 June 2019
First published online: 12 July 2019

Key words:

Bats; Haemosporida; *Hepaticystis*; Nigeria; Pteropodidae; *Rousettus*.

Author for correspondence:

J. Schaer, E-mail: schaerju@hu-berlin.de

Survey of *Hepaticystis* parasites of fruit bats in the Amurum forest reserve, Nigeria, identifies first host record for *Rousettus aegyptiacus*

N. Atama^{1,2}, S. Manu¹, S. Ivande¹, S. P. Roskopf^{3,4}, K. Matuschewski^{3,4}
and J. Schaer^{3,4,5}

¹A. P. Leventis Ornithological Research Institute, Jos, Nigeria; ²Veterinary Department, Kaduna State Ministry of Agriculture and Forestry, Kaduna, Nigeria; ³Department of Molecular Parasitology, Institute of Biology, Humboldt University, 10115 Berlin, Germany; ⁴Parasitology Unit, Max Planck Institute for Infection Biology, Berlin, 10117, Germany and ⁵Department of Biological Sciences, Macquarie University, North Ryde, 2109, Australia

Abstract

Parasites of the genus *Hepaticystis* are close relatives of *Plasmodium* that frequently infect epauletted fruit bats across West and East Africa. Our understanding of susceptible hosts and prevalence of infection of *Hepaticystis* remains fragmented. Non-invasive sampling of bat assemblages in representative habitats critically contribute to haemosporidian parasite distribution maps. Here, we report on a survey of *Hepaticystis* parasite infections in bats undertaken over two consecutive years in a protected area in Nigeria, where prevalence and diversity of bat-infecting haemosporidian parasites have not been studied. Microscopic examination of blood films in combination with PCR detection and sequencing revealed *Hepaticystis* infections with prevalences of 25% and 42% in the closely related epauletted fruit bats *Epomophorus* sp. and *Micropteropus pusillus*. For the first time, mature *Hepaticystis* gametocytes were identified in one Egyptian fruit bat (*Rousettus aegyptiacus*). This novel host record was confirmed by parasite and host genotyping and suggests that *Hepaticystis* parasites have a broader host distribution in African fruit bats than currently known.

Introduction

Malarial parasites (Phylum: Apicomplexa, Order: Haemosporida) are eukaryotic protozoan parasites that infect a diversity of vertebrate hosts such as birds, squamate lizards and mammals (Garnham, 1966; Perkins and Schaer, 2016). Bats, with over 1349 species (Simmons, 2005; Miller-Butterworth *et al.*, 2007; Lack *et al.*, 2010) are mammalian hosts to a large diversity of haemosporidian parasites (e.g. Schaer *et al.*, 2013). Phylogenetic analyses suggest that bats were likely the first mammals to acquire infections with haemosporidians before subsequent transmission to other non-chiropteran mammals (Schaer *et al.*, 2013; Lutz *et al.*, 2016). Bats are parasitized by nine different haemosporidian genera, seven of which are exclusive to them (Perkins and Schaer, 2016). The haemosporidian genera that infect bats include *Plasmodium*, *Hepaticystis*, *Polychromophilus* and *Nycteria* with each of these being host-specific to particular bat families within the order Chiroptera (Schaer *et al.*, 2013). Chiropteran haemosporidians are therefore important for the study of the evolution of malaria parasites (Perkins and Schaer, 2016). Gaining insights on the ecology and evolution of bat malaria parasites and its potential impacts on the hosts systems will guide future conservation efforts and advance studies on the impacts parasites have on hosts.

Nigeria is a biodiversity hotspot for bats with approximately 71 described species distributed within the country (IUCN, 2017). Here, we investigated the prevalence and phylogenetic relationships of haemosporidian parasites among bats in Nigeria.

Materials and methods

Bats were sampled in the Amurum Forest Reserve (9°53'N, 8°59'E) which is located in Laminga village, 15 km northeast of Jos, Plateau state, North-Central Nigeria during May and June in 2015 and 2016 at twelve different sites (Fig. 1A, Table S1). Bats were captured opportunistically using ground-level mist nets and canopy nets and kept individually in cloth bags prior to sampling. Standard measurements including sex, age and reproductive condition were recorded and species identified using the key of Rosevear (1965). The responsible institution for the approval of the use of Amurum Forest Reserve for research, the Scientific and Research Ethics Committee of the A. P. Leventis Ornithological Research Institute (APLORI), reviewed and officially approved this survey (4 May 2015).

Blood samples were collected by pricking the cephalic vein with a sterile 27G needle and collecting approximately 100 µL of blood into heparinized capillary tubes (samples from 2015) or dotted on FTA® DNA cards (samples from 2016). Blood from the capillary tubes was immediately used to prepare thin blood smears, which were air-dried and fixed in 99–100% (vol/vol) ethanol for five minutes. Sampled bats were marked with commercial

© Cambridge University Press 2019. This is an Open Access article, distributed under the terms of the Creative Commons Attribution licence (<http://creativecommons.org/licenses/by/4.0/>), which permits unrestricted re-use, distribution, and reproduction in any medium, provided the original work is properly cited.

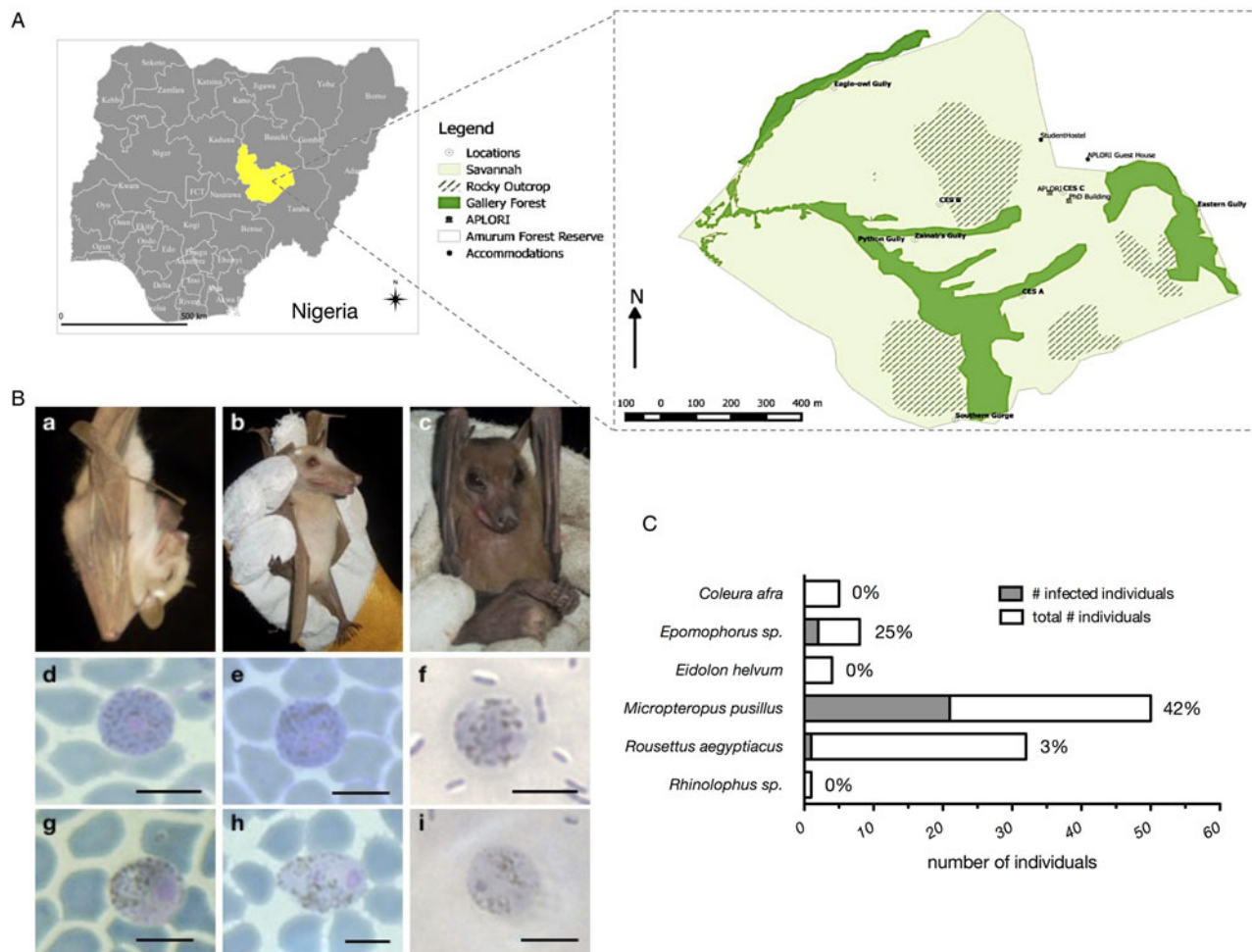


Fig. 1. (A) Amurum Forest Reserve in Jos plateau state Nigeria. The site covers an area of about 300 hectares with a mean annual rainfall of 1375–1750 mm per annum and a mean temperature of 10 °C during the cold season (December–February) and 32 °C during the hot season (April–May). The vegetation is a rocky outcrop in dry scrub savannah with gallery forests and patches of grassland. Bats were sampled at 12 sites, which cover all three habitat types, Savannah (light green), gallery forests (dark green), and rocky outcrops (striped), during May/June of 2015 and 2016. The maps were generated with QGIS. (B) Host species and representative micrographs of *Hepatocystis* blood stages. Shown are examples of the infected pteropodid bats, *Micropteropus pusillus* (a), *Epomophorus* sp. (b), and *Rousettus aegyptiacus* (c). Micrographs depict macrogametocytes (d = FB50, *M. pusillus*; e = FB31, *M. pusillus*; f = FB12, *R. aegyptiacus*) and microgametocytes (g = FB51, *M. pusillus*; h = FB52, *M. pusillus*; i = FB12, *R. aegyptiacus*). Only mature stages of gametocytes were detected, featuring bright-blue (macrogametocytes, d, e, f) or biscuit-coloured (microgametocytes, g, h, i) cytoplasm and coarse pigments as described for *Hepatocystis* in other African epauletted bats (e.g. Garnham, 1966). The nucleus of the microgametocytes was characteristically surrounded by a pigment-free area. Magnification is 1000 \times . Size bars = 5 μ m (C) Prevalence of haemosporidian infections in %.

nail polish on their hind claws to avoid short-term re-sampling and were released at the capture site.

Blood smears were re-fixed with 99–100% (vol/vol) ethanol or methanol prior to Giemsa staining. Screening of stained blood smears and morphological identification of haemosporidian parasites were performed using light microscopy (Nikon Instrument Inc., USA) under oil immersion at 1000 \times magnification (Fig. 1B).

DNA was extracted from unstained blood smears on glass slides that was removed using a sterile razor blade (2015 samples) or from FTA cards (2016 samples). All DNAs were extracted using the Qiagen DNeasy extraction kit (Hilden, Germany), using products protocol for animal tissues with elution volumes of 30 and 60 μ L for the 2015 and 2016 blood samples respectively. PCRs were performed using the QIAGEN TopTaq Master Mix. The mitochondrial gene cytochrome *b* (*cytb*) was amplified with the primer sets DW2/3932R and Hep-F3/Hep-R3 and the nuclear elongation factor 2 gene (*ef2*) using the primers EF2-F/EF2-R (Schaer *et al.*, 2013). The apicoplast caseinolytic protease (*clpC*) was amplified using nested PCR (Martinsen *et al.*, 2008) (Table S2). All PCR products were sequenced with the amplification primers in both directions using BigDye v3.0 (Applied Biosystems) and run on an ABI-373 sequencer. In order to verify

morphological bat species identifications, bat genetic markers comprising nuclear introns and protein-coding genes (*acox2*, *fgb*, *rogdi*, *rag1*, *rag2*) were amplified and sequenced (Tables S2 and S3).

Parasite and bat DNA sequences were edited using Geneious version 8.1.9 software, with ambiguous positions or missing data coded with N' and sequences aligned using the Muscle algorithm (Edgar *et al.*, 2004). Parasite sequences included 906 nucleotides (nt) of *cytb*, 528 nt of *clpC* and 516 nt of the nuclear *ef2*-gene (Table S3). Reference sequences, including the major mammalian haemosporidian clades and *Hepatocystis* sequences from primates and African bats were retrieved from GenBank and added to the alignments (Table S3). Sequence alignments of the three genes *cytb*, *clpC* and *ef2* were concatenated and phylogenetic relationships were evaluated with Bayesian inference methods using *Leucocytozoon* as outgroup taxon. Data were divided into partitions according to the three genes and PartitionFinder vs.2 was used to test different DNA substitution models and partition schemes (Lanfear *et al.*, 2017). Bayesian inference was conducted in MrBayes v3.2.6 (Huelsenbeck and Ronquist, 2001), via the CIPRES Science Gateway Web Portal V3.3 (Miller *et al.*, 2010) with two runs of four chains (three

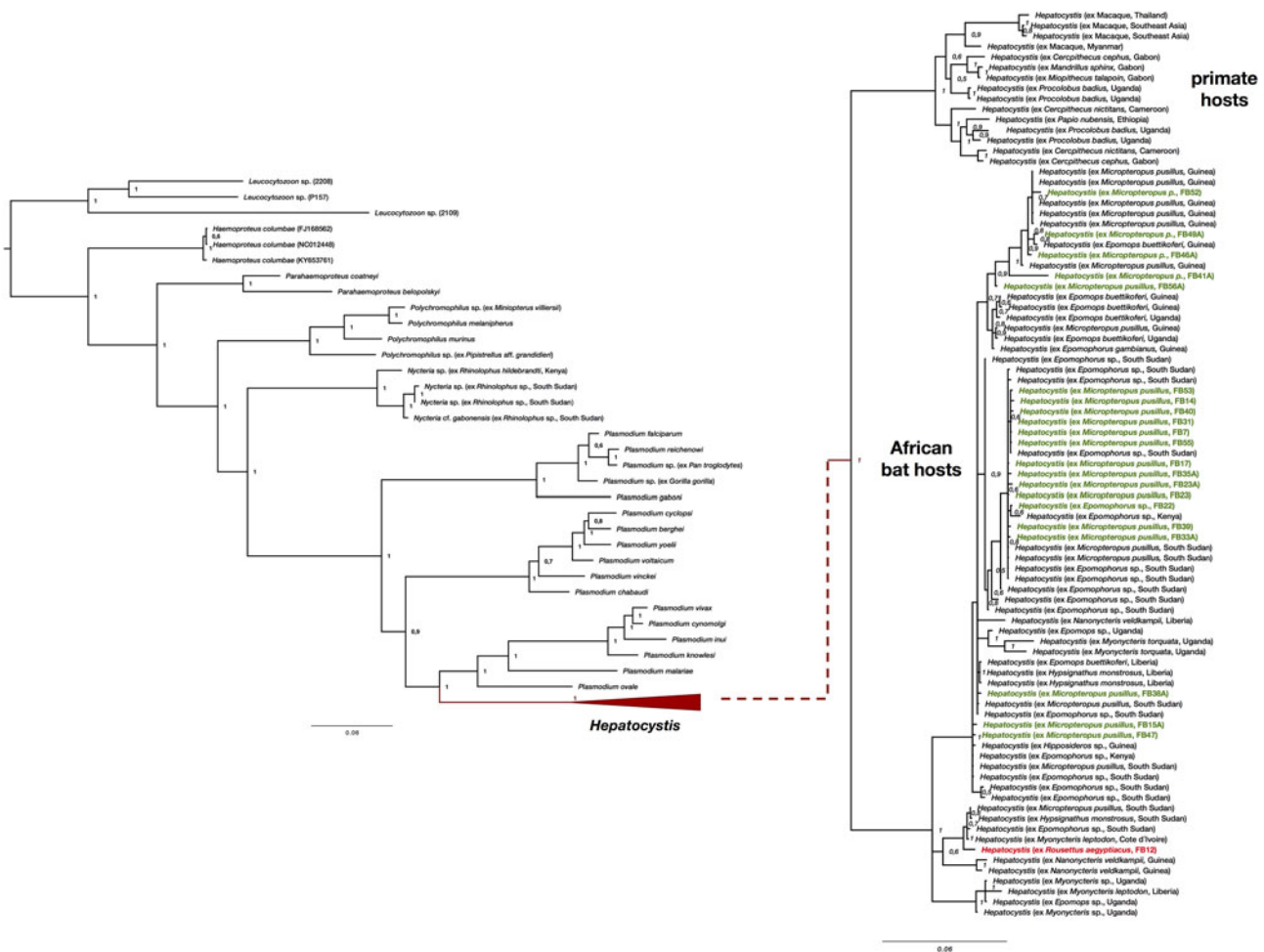


Fig. 2. Phylogenetic analysis of *Hepatocystis* parasites in the context of the major haemosporidian clades recovered by Bayesian analysis. Posterior probabilities are given. The analysis was performed on the concatenated alignment (total of 1947 bp) of the mitochondrial cytochrome *b* (906 bp), the apicoplast caseinolytic protease (538 bp), and the nuclear elongation factor 2 (516 bp). (A) Placement of *Hepatocystis* as collapsed clade as sister to the mammalian *Plasmodium* (*Plasmodium*) clade comprising *Plasmodium vivax* and *Plasmodium ovale*, as shown before (e.g. Schaer *et al.*, 2013). (B) The uncollapsed clade contains representative reference sequences of *Hepatocystis* of primate hosts as well as African bat hosts. The samples of the current study are highlighted in bold (parasite sequences from *Epomophorus* and *Micropteropus* hosts in green, the sequence from *Rousettus* in red). Sequences of the Nigerian samples closely group within the *Hepatocystis* parasite clades of epauletted fruit bat species from different African countries and no host species specificity is apparent. The *Hepatocystis* sequences of *R. aegyptiacus* group among the parasite sequences of epauletted fruit bat species from South Sudan and with sequences from parasites of *Myonycteris* from Cote d'Ivoire and slightly differ from the Nigerian *Epomophorus* and *Micropteropus* parasite sequences.

heated, one cold, temperature = 0.03) each for 10 million generations. The first 25% of trees were discarded as burn-in. Tracer v1.6 (Rambaut *et al.*, 2014) was used to assess mixing and convergence of runs and effective sample size (ESS > 500). Phylogenetic trees were visualized with the program FigTree (<http://tree.bio.ed.ac.uk/software/figtree/>).

Results

A total of 100 bats of six species belonging to three families were caught at nine of the twelve sites within Amurum Forest Reserve (Fig. 1A, Tables S1 and S4). The majority of the bats (95%) belonged to the fruit bat family Pteropodidae, with the four species: *Epomophorus* sp., *Micropteropus pusillus*, *Eidolon helvum* and *Rousettus aegyptiacus*. In addition, a single *Rhinolophus* sp. (Rhinolophidae) and five *Coleura afra* (Emballonuridae) were captured. The overall prevalence of haemosporidian parasites was 25% (25/100) with parasites exclusively detected in the bat family Pteropodidae (Fig. 1C, Table S4). The two epauletted fruit bat genera *Micropteropus* and *Epomophorus* had a parasite prevalence of 42% (21/50) and 25% (2/8), respectively. We further detected a haemosporidian infection in the single *R. aegyptiacus* (3%, 1/32) that was sampled.

The morphology of the gametocyte blood stages of the parasites corresponds to the descriptions of *Hepatocystis* parasites of epauletted fruit bats from Guinea, Liberia, Cote d'Ivoire and South Sudan (Schaer *et al.*, 2013, 2017) (Fig. 1B). The phylogenetic analysis confirmed all parasites as belonging to the genus *Hepatocystis*. Sequences of the samples of the study closely group within the *Hepatocystis* parasite clades of epauletted fruit bat species from different African countries (Fig. 2). No host species specificity is apparent, which is in agreement with previous findings of *Hepatocystis* in bats (Schaer *et al.*, 2017). The analyses confirmed *Hepatocystis* as monophyletic clade (posterior probability of 1) with the African bat *Hepatocystis* sequences grouping in one monophyletic subclade as previous studies have shown (Fig. 2) (Schaer *et al.*, 2017). The *Hepatocystis* sequences of the infected *R. aegyptiacus* individual group among the parasite sequences of the epauletted fruit bats. However, compared to all other Nigerian samples of the study, the parasite sequences of *R. aegyptiacus* slightly differ (e.g. 28 unique bases across 890 nt of the *cytb* sequence, representing a 3% sequence divergence) and do not group with the other Nigerian sequences, but with sequences from parasites of *Myonycteris* from Cote d'Ivoire and diverse epauletted hosts from South Sudan (Fig. 2).

Discussion

This study provides the first information on the haemosporidian parasites of bats in Nigeria through an investigation of bat malaria parasites in the Amurum Forest Reserve. *Hepatocystis* was discovered in epauletted fruit bats in Nigeria and the study strengthens the notion that the bat genera *Epomophorus* and *Micropteropus* present common hosts of *Hepatocystis* parasites in several African countries. The prevalences (of 25 and 42%) are similar to previous reports from epauletted fruit bats in other West, Central and East African countries (e.g. Schaer *et al.*, 2013; Lutz *et al.*, 2016; Boundenga *et al.*, 2018) with the exceptions of the studies in South Sudan and Central Gabon (Schaer *et al.*, 2017; Roskopf *et al.*, 2019). The study in South Sudan revealed *Hepatocystis* infections in over 80% of the investigated epauletted fruit bats and in contrast, the study in Central Gabon reported no haemosporidian infections in the epauletted fruit bats (Schaer *et al.*, 2017; Roskopf *et al.*, 2019). For the first time, a *Hepatocystis* infection is reported for the pteropodid host *R. aegyptiacus*. Compared to the commonly infected epauletted fruit bats that roost in small groups in trees, *R. aegyptiacus* features a different roosting behaviour, forming large cave-dwelling colonies (e.g. ACR., 2017). To date, only *Plasmodium* infections have been documented for this bat species. *Plasmodium* (*Vinckeia*) *rousetti* was described from *Rousettus leachi* (old synonym for *R. aegyptiacus*) in the Democratic Republic of the Congo (van Riel and Hiernaux-L'Hoest, 1951) and subsequently reported from the same species (de Faveaux, 1958; Garnham, 1966). Apart from these three studies, which date back well over 50 years ago, no infections with haemosporidian parasites have been re-discovered in *R. aegyptiacus* (e.g. Schaer *et al.*, 2013; Lutz *et al.*, 2016; Boundenga *et al.*, 2018; Roskopf *et al.*, 2019). Strikingly, here we detected *Hepatocystis* parasites, and not the previously reported *Plasmodium* species in this bat host. The close phylogenetic relationships of *Plasmodium* and *Hepatocystis* parasites (Galen *et al.*, 2018) raise the possibility that the previous reports of *P. rousetti* might instead be *Hepatocystis* infections, as reported herein. However, the morphological description of *Plasmodium* in *R. aegyptiacus* was based on the detection of schizont stages in the blood (van Riel and Hiernaux-L'Hoest, 1951), a life cycle stage that is lacking in *Hepatocystis* parasites. Additional investigations of *R. aegyptiacus* are needed to gain a better understanding of what appear to be rare infections of *Hepatocystis* parasites in this host species. The low prevalence of *Hepatocystis* in this study, and the lack of positive records in previous studies suggests that *R. aegyptiacus* might not represent a common host for *Hepatocystis*, and that detected cases are rare events that may perhaps be related to vector feeding preferences.


The blood smear of the infected *R. aegyptiacus* individual was of poorer quality than usual, as it was prepared after two days of blood storage. However, several mature gametocytes were readily detectable, and the morphology complies with descriptions of *Hepatocystis* (Fig. 2C–f, i). The presence of gametocytes in the blood confirms *R. aegyptiacus* as a true host as these life cycle stages present the proof that the parasite has completed its life cycle in the tissue and subsequently in the blood of the vertebrate host. Most importantly, the gene sequences unambiguously identify the infection as belonging to *Hepatocystis*. By sequencing different nuclear markers for the infected *R. aegyptiacus* we confirmed the morphological identification of the host sample as *R. aegyptiacus*.

Bats of the genus *Rhinolophus* as well as emballonurid bats have been reported as hosts of *Nycteria* parasites (Perkins and Schaer, 2016). In this study, no haemosporidian parasites were detected in samples of the two insectivorous bat species *C. afro* and *Rhinolophus* sp. However, the sample size for these species

was considerably small, a more elaborate cross-sectional sampling of the insectivorous bats in the area is needed to further investigate haemosporidian parasites in this bat group.

In conclusion, a survey of haemosporidian parasites in bats in two consecutive years in a protected savannah habitat in the Jos plateau, Nigeria, revealed abundant *Hepatocystis* infections in pteropodid hosts and uncovered a previously unknown competent host, *R. aegyptiacus*, for complete *Hepatocystis* blood stage maturation.

Supplementary material. The supplementary material for this article can be found at <https://doi.org/10.1017/S0031182019000817>

Author ORCIDs.  Juliane Schaer, 0000-0001-6714-5771.

Acknowledgements. We would like to thank Tigga Kingston, Kendra Phelps, Iroro Tanshi, Chima Nwaogu and Joshua Kamani. We further want to thank John Azi for assistance in the field.

Financial support. This work was supported in part by the Max Planck Society and the Humboldt University Berlin.

Conflict of interest. None.

Ethical standards. The responsible institution for the approval of the use of Amurum Forest Reserve for research, the Scientific and Research Ethics Committee of the A. P. Leventis Ornithological Research Institute (APLORI), reviewed and officially approved this survey (4 May 2015).

References

- ACR (2017) African Chiroptera Report 2017. AfricanBats NPC, Pretoria. i–xxi, 1–7635 pp. doi: 10.13140/RG.2.2.18439.09129.
- Boundenga L, Ngoubangoye B, Mombo IM, Tsoumbo AT, Renaud F, Rougeron V and Prugnolle F (2018) Extensive diversity of malaria parasites circulating in Central African bats. *Ecology and Evolution* **8**, 10578–10586.
- de Faveaux DFA (1958) Speologica africana: chiropteres des grottes du Haut-Katanga (Congo Belge). *Bulletin de l'Institut Francais d'Afrique Noire. Serie A. Sciences Naturelles, Dakar* **20**, 263–275.
- Edgar RC, Drive RM and Valley M (2004) MUSCLE: multiple sequence alignment with high accuracy and high throughput. *Nucleic Acids Research* **32**, 1792–1797. <https://doi.org/10.1093/nar/gkh340>.
- Galen SC, Borner J, Martinsen ES, Schaer J, Austin CC, West J and Perkins SL (2018) The polyphyly of *Plasmodium*: comprehensive phylogenetic analyses of the malaria parasites (order Haemosporida) reveal widespread taxonomic conflict. *Royal Society Open Science* **5**, 171780.
- Garnham PCC (1966) *Malaria Parasites and Other Haemosporidia*. Oxford, UK: Blackwell Scientific Publications.
- Huelsenbeck J and Ronquist F (2001) MRBAYES: Bayesian inference of phylogenetic trees. *Bioinformatics Applications Note* **17**, 754–755. <https://doi.org/10.1093/bioinformatics/17.8.754>
- IUCN (2017) *Chiroptera Nigeria [www Document]*. Retrieved from IUCN Red List Threat. Species. Version 2017-1 website. Available at <http://www.iucnredlist.org> (Accessed 10 December 2018).
- Lack JB, Roehrs ZP, Stanley Jr CE, Ruedi M and Van Den Bussche RA (2010) Molecular phylogenetics of *Myotis* indicate familial-level divergence for the genus *Cistugo* (chiroptera). *Journal of Mammalogy* **91**, 976–992. <https://doi.org/10.1644/09-MAMM-A-192.1>.
- Lanfear R, Frandsen PB, Wright AM, Senfeld T and Calcott B (2017) PartitionFinder 2: new methods for selecting partitioned models of evolution for molecular and morphological phylogenetic analyses. *Molecular Biology and Evolution* **34**, 772–773.
- Lutz H, Patterson BD, Kerbis Peterhans JC, Stanley WT, Webala PW, Gnoske TP, Hackett SJ and Stanhope MJ (2016) Diverse sampling of East African haemosporidians reveals chiropteran origin of malaria parasites in primates and rodents. *Molecular Phylogenetics and Evolution* **99**, 7–15.
- Martinsen ES, Perkins SL and Schall JJ (2008) A three-genome phylogeny of malaria parasites (*Plasmodium* and closely related genera): evolution of life-history traits and host switches. *Molecular Phylogenetics and Evolution* **47**, 261–273.

- Miller MA, Pfeiffer W and Schwartz T (2010) Creating the CIPRES science gateway for inference of large phylogenetic trees. In: *Proceedings of the Gateway Computing Environments Workshop (GCE)*, 14 Nov 2010, pp. 1–8. New Orleans, LA. Available at <https://ieeexplore.ieee.org/document/5676129>.
- Miller-Butterworth CM, Murphy WJ, O'Brien SJ, Jacobs DS, Springer MS and Teeling EC (2007) A family matter: conclusive resolution of the taxonomic position of the long-fingered bats, *Miniopterus*. *Molecular Biology and Evolution* **24**, 1553. <https://doi.org/10.1093/molbev/msm076>.
- Perkins SL and Schaer J (2016) A modern menagerie of mammalian Malaria. *Trends in Parasitology* **32**, 772–782.
- Rambaut A, Suchard M, Xie D and Drummond A (2014) *Tracer v1.6*. Available at <https://beast.bio.ed.ac.uk/Tracer>.
- Rosevear DR (1965) *The Bats of West Africa*. London: Trustees of the British Museum (Natural History).
- Roskopf SP, Held J, Gmeiner M, Mordmüller B, Matsiégui P, Eckerle I, Weber N, Matuschewski K and Schaer J (2019) *Nycteria* and *Polychromophilus* infections of bats in Central Gabon. *Infection Genetics and Evolution* **68**, 30–34.
- Schaer J, Perkins SL, Decher J, Leendertz FH, Fahr J, Weber N and Matuschewski K (2013) High diversity of West African bat malaria parasites and a tight link with rodent *Plasmodium* taxa. *Proceedings of the National Academy of Sciences of the United States of America* **110**, 17415–17419.
- Schaer J, Perkins SL, Ejotre I, Vodzak ME, Matuschewski K and Reeder DM (2017) Epauletted fruit bats display exceptionally high infections with a *Hepatocystis* species complex in South Sudan. *Scientific Reports* **7**, 6928.
- Simmons NB (2005) Chiroptera. In Wilson D and Reeder DM (eds), *Mammal Species of the World: A Taxonomic and Geographic Reference*. Baltimore: Johns Hopkins University Press, pp. 312–529.
- van Riel J and Hiernaux-L'Hoest J (1951) Description of a *Plasmodium* found in a bat, *Roussettus leachi*. *Parasitology* **41**, 270–273. <https://doi.org/10.1017/S0031182000084109>.